

Histoarchitectural and Behavioral Characterization of the Prefrontal Cortex of Type 2 Diabetes Mellitus Male Wistar Rat and Neuroprotective Role of Virgin Coconut Oil

J. A. Olanrewaju^{1*}, S. Y. Olatunji¹, J. O. Owolabi¹, O. S. Fabiyi¹, U. E. Ukonne¹ and A. B. O. Desalu¹

¹Department of Anatomy, Ben S. Carson [Snr.] School of Medicine, Babcock University, Ilishan Remo, Ogun State, Nigeria.

Authors' contributions

This work was carried out in collaboration between all authors. Author JAO designed the study and wrote the protocol. Authors SYO and JOO wrote the first draft of the manuscript and performed the statistical analysis. Authors JAO, JOO and ABOD managed the analyses of the study. Authors UEU and JAO managed the literature searches. All authors read and approved the final manuscript.

Article Information

DOI: 10.9734/INDJ/2017/35218

Editor(s):

(1) Zhefeng Guo, Department of Neurology, University of California, Los Angeles, USA.

Reviewers:

(1) Nazan Uysal, Dokuz Eylul University, Turkey.

(2) Ivan Simic, University of Kragujevac, Serbia.

Complete Peer review History: <http://www.sciedomain.org/review-history/23448>

Original Research Article

Received 1st July 2017
Accepted 30th January 2018
Published 5th March 2018

ABSTRACT

Aims: This research is aimed at investigating the possible effects of Virgin Coconut Oil on Histomorphology of the prefrontal cortex of type 2 diabetes male Wistar rat.

Study Design and Methodology: Animals used for this research experiment was 32 male Wistar rats, and were grouped as follows;

Group A- Control group received water and feed *ad libitum*.

Group B – Received 0.6ml of Virgin coconut oil for 56 days

Group C – Received High-fat diet and 35 mg/kg of streptozotocin for 3days

Group D – Received High-fat diet *ad libitum* for 56days, 35mg/kg of streptozotocin for 3 days and then 0.6ml virgin coconut oil for 28 days.

The body weights of the animals were measured every week using a weighing balance. The

*Corresponding author: E-mail: olanrewaju@babcock.edu.ng, afeesjohn@yahoo.com;

neurobehavioral analysis was carried out using Barnes maze to measure spatial learning and memory. The animals were sacrificed by cervical dislocation at the end of the experiment and the tissue removed for histological procedures which include: Haematoxylin & Eosin, and Cresyl fast Violet.

Place and Duration of Study: This work was carried out at Department of Anatomy Ben Carson School of Medicine Babcock University Ilishan Remo, Ogun State Nigeria and the experiment started on the 1st of February and ended on the 14th of March, 2017.

Results: Diabetes mellitus group lost a significant amount of weight, But the Virgin Coconut oil group animals added a significant amount of weight which suggests that VCO helps improve appetite.

The diabetes mellitus group had the highest latency in the Barnes maze test while the Virgin Coconut Oil group had the lowest primary latency.

Normal histological features of the Control and VCO treated (control) groups did not show any observable altered panoramic morphological presentation of the PFC layers. VCO treated group showed slight degenerative changes (yellow arrows) and STZ group showed induced degenerative changes in the cortex and was characterized by fragmented pyramidal and granule cell layer with observable pyknotic cells.

Conclusion: Diabetes affected the prefrontal cortex negatively while virgin coconut oil seems to neutralize the adverse effect and tried to restore the integrity of the prefrontal cortex.

Keywords: Diabetes; virgin coconut oil (VCO); streptozotocin (STZ); prefrontal cortex.

1. INTRODUCTION

1.1 Background of Study

Diabetes mellitus (DM) is probably one of the oldest diseases known to man. It is a chronic metabolic disorder in which prevalence has been increasing steadily all over the world. Globally an estimated 422 million adults are living with Diabetes mellitus [1]. Diabetes at least doubles a person's risk of early death, with equal rates in both male and females. In 2012 there were 1.5 million deaths worldwide directly caused by diabetes, It was the eighth leading cause of death among both sexes and the fifth leading cause of death in women in 2012 [1].

There are two main types of diabetes mellitus:

- i. Type 1 diabetes, also called insulin dependent diabetes mellitus (IDDM), is caused by lack of insulin secretion by beta cells of the pancreas. Type 1 diabetes is the result of an autoimmune reaction to proteins of the islets cells of the pancreas [2].
- ii. Type 2 diabetes, also called non-insulin dependent diabetes mellitus (NIDDM), is caused by decreased sensitivity of target tissues to insulin.

The reduced sensitivity to insulin is often called insulin resistance. In both types of diabetes mellitus, metabolism of all the main foodstuffs is altered. The basic effect of insulin deficiency or

insulin resistance on glucose metabolism is to prevent the efficient uptake and utilization of glucose by most cells of the body, except those of the brain [3].

Type 2 Diabetes mellitus was first described as a component of metabolic syndrome in 1988 [4]. The majority of the Diabetes mellitus burden in Africa appears to be type 2 Diabetes Mellitus, with less than 10% of Diabetes Mellitus cases being type 1 Diabetes Mellitus. Type 2 Diabetes Mellitus (formerly known as non-insulin dependent Diabetes mellitus) is the most common form of Diabetes mellitus characterized by hyperglycemia, insulin resistance, and relative insulin deficiency [5]. In Type 2 Diabetes mellitus, insulin is no longer able to reduce the levels of blood glucose after a meal. The reason for this in most cases is that the insulin messenger signal no longer triggers the cellular cascade of events that leads to an increased uptake of glucose by cells [6].

Type 2 diabetes appears to be related to aging, inactive lifestyle, genetic influence, and obesity. As a result of this trend, it is fast becoming an epidemic in some countries of the world. In the condition, the body usually still produces a smaller amount of insulin but persistently high intakes of dietary sugars lead to excess demand on insulin production and the body cells do not properly respond to insulin, which leads to insulin resistance over time. Type 2 Diabetes mellitus has been seen to have an effect on the cognitive process which is one of the major functions of

the prefrontal cortex. The present studies have confirmed that Type 2 Diabetes Mellitus is a robust risk factor for cognitive dysfunction. However, the precise mechanisms remain to be elucidated [7]. In Luchsinger and colleagues' study [8], the results indicated that Diabetes mellitus is related to a relatively higher risk for all causes of Mild Cognitive Impairment.

Overtime type 2 diabetes mellitus could lead to long-term medical problems such as;

- Stroke
- Heart disease
- Dental problems
- Stroke
- Foot problems
- Nerve damage
- Kidney problems, etc.

Increased oxidative stress is a widely accepted participant in the development and progression of diabetes and its complications [9]. It is believed that oxidative stress plays important role in the development of vascular complications in diabetes particularly type 2 diabetes [10]. In diabetes mellitus, main sources of oxidative stress are mitochondria. During oxidative metabolism in mitochondria, a component of the utilized oxygen is reduced to water, and the remaining oxygen is transformed to oxygen free radical which is an important ROS [11].

1.2 The Prefrontal Cortex

The Prefrontal cortex is the anterior part of the frontal lobes of the brain, lying in front of the motor and premotor areas. The prefrontal cortex is also called the dorsolateral prefrontal cortex. It comprises several Brodmann areas (BAs) anterior to the primary motor and premotor cortex. The PFC is involved in higher-level cognitive processes grouped under the term of "executive functions" in humans, including mostly dorsolateral areas, like BA 9, 10, and 46 [12]. The prefrontal cortex can be seen as the executive center of the brain. The frontal lobe and the portion of it occupied solely by association cortex, the prefrontal cortex, are eternally popular areas to research in human brain evolution due to their functional attributes.

1.3 Type 2 Diabetes and the Prefrontal Cortex

Cognition is defined as "the mental action or process of acquiring knowledge and understanding through thought, experience, and

the senses" (Oxford dictionary). Cognition is known as one of the major functions of the prefrontal cortex.

Diabetes Mellitus is related to 40% higher rate of mild cognitive impairment [8]. This is especially true when diabetes starts before the age of 65, or when the disease is more than 10 years. Treatment with insulin and the presence of diabetes complications such as retinopathy are other risk factors [13,14]. Insulin and its signaling pathways not only regulate glucose and energy metabolism but also modulate learning and memory [15]. As cognition-related structures such as the prefrontal cortex have a high density of insulin receptors and can produce insulin locally, an obstacle in any of the insulin signaling pathways can give rise to cognitive dysfunction most of which relates to memory, attention and executive functions [16].

In a large cross-sectional study, Moran et al. [17] reported that patients with T2DM had lower total grey, white, and hippocampal volumes. Regions with loss of grey matter include the medial temporal, anterior cingulate, and medial frontal lobes. White matter loss (WML) was found in the frontal and temporal regions. These investigators determined that brain volume loss was associated with poor performance in cognitive testing in these patients with T2DM. Other studies have suggested that atrophy may be greater in the prefrontal region in patients with T2DM [18,19]. Patients with T2DM have also been shown to have increased WMLs brain atrophy and WMLs have been associated with cognitive dysfunction in some but not all studies [20].

1.4 Virgin Coconut Oil

Virgin coconut oil is obtained from the fresh, mature kernel of the coconut by mechanical or natural means, with or without the use of heat, without undergoing chemical refining, bleaching or deodorizing, and which does not lead to the alteration of the nature of the oil [21]. It may retain native bioactive compounds present in it [22]. VCO extracted in cold and hot conditions is known to be rich in polyphenols. It is suitable for consumption without the need for further processing. It was developed to meet the needs of the natural foods market that advocate minimal processing of products. In recent years, virgin coconut oil has gained popularity as a nutraceutical. Promoted as a dietary supplement designed to optimize health through improved nutrition, it is said to be of benefit for patients

with various ailments. Unlike coconut (copra) oil, it is endowed with the natural antioxidant. Flavonoids and other polyphenols may be responsible for the antioxidant properties of VCO.

1.5 Virgin Coconut Oil and Type 2 Diabetes Mellitus

In diabetic patients, antioxidants may play a vital role in improving insulin response to the loaded glucose and may reduce insulin resistance. Antioxidant enzymes are a critical part of cellular protection against reactive oxygen species and ultimately oxidative stress. Since, oxidative stress contributes significantly to the pathophysiology of diabetes [23], substances that suppress oxidative stress might be therapeutically beneficial. Studies have shown that exogenously administered antioxidants have protective effects on diabetes, thus providing insight into the relationship between free radicals and diabetes [23].

As our local and global population increases there is a proportionate increase in the number of individuals with diabetes also increases; although the prevention of Type 2 Diabetes mellitus (T2 Diabetes Mellitus) is promoted worldwide there is still an increase in the population of people with diabetes. Present studies have confirmed that T2 Diabetes Mellitus is a robust risk factor for cognitive dysfunction. However, the precise mechanisms remain unclear⁽⁷⁾. Interestingly, insulin has direct effects on brain activity and cognitive processes. The impairment of insulin activity in the brain leaves neurons more exposed to toxic influences which could lead to cognitive dysfunction. To date, there are no clear treatments to help improve cognitive decline in patients with T2 Diabetes Mellitus [24]. This research is to try and investigate if Virgin Coconut oil will help improve cognitive dysfunction in a diabetic condition.

2. MATERIALS AND METHODS

The model animals used for this research experiment was the juvenile male Wistar rat, 32 male Wistar rats were used for the sake of this experiment. The Wistar rats were purchased from Babcock university animal house. The rats were left to acclimatize in Babcock university animal house for a period of 2 weeks. This was done to enable the rats to adapt to the new environment.

2.1 High Fat Diet

The high-fat diet is compounded following the formula in the Table 1 below:

Table 1. Tabular representation of the compositions of the High Fat Diet

S/No	Ingredients	High Fat Diet (g/kg)
1.	Corn Starch	276
2.	Soya Beans	180
3.	Rice Husk (cellulose)	40
4.	Sucrose	80
5.	Soya bean Oil	50
6.	Vitamin/mineral mix	40
7.	Methionine	4
8.	Lard/Fat	330
9.	Total	1000g

2.2 Experimental Design

The research was designed thus (Table 2):

The 32 Wistar rats were weighed at the end of the acclimatization period after which they were grouped into 4 with each group having 8 rats each. The groups are as follows;

- Group A – the control group was given only water and feed *ad libitum*.
- Group B – this group was given 0.6ml of Virgin coconut oil using an oral cannula for 56days
- Group C – this group was given High-fat diet *ad libitum* and 35mg/kg of streptozotocin for 56days to induce type 2 diabetes mellitus
- Group D – this group was given High-fat diet *ad libitum* for 56days, 35mg/kg of streptozotocin for 3 days from the 28th day to day 31, and then 0.6ml virgin coconut oil for 28 days to induce damage and then treatment.

During the course of this experiment, the rats were weighed weekly to monitor their weights and any possible changes that could occur.

2.3 Streptozotocin

Streptozotocin was obtained in the solid state.

0.38 g of Citrate was mixed in 20 ml of distilled water in a sample bottle.

0.516 g of sodium citrate salt was mixed in 20 ml of distilled water in a sample bottle.

5 ml of both was used as a buffer for the streptozotocin mixture.

Table 2. Table showing treatment regimen design for control and experimental groups

S/N	Group	Treatments	Dosages [mg/kg]	Rationale	Duration [days]	No. of Animals
1.	Control [CO]	Water	<i>Ad libitum</i>	Placebo	56	8
2.	Experimental B [VCO]	Virgin coconut oil	1700	Positive Control	56	8
3.	Experimental C [HFD+STZ]	High fat diet +streptozotocin	<i>Ad libitum</i> + 35	Negative Control	56	8
4.	Experimental D [HFD+STZ+VCO]	High-fat diet +streptozotocin then virgin coconut oil	<i>Ad libitum</i> + 35 1700	Therapeutic effect- to induce damage then treatment	56 3 28	8

2.4 Virgin Coconut Oil Preparation

- The solid endosperm of matured coconuts was procured at the fruit grocery and authenticated as *Cocos nucifera* was done at the plant biology department of the University of Ilorin.
- The VCO was extracted using a modified wet extraction method described by Nevin and Rajamohan [25,26].
- The solid endosperm of mature coconut was crushed and made into a aluminium chlorides slurry.
- About 500 ml of water was added to the slurry obtained and squeezed through a fine sieve to obtain coconut milk.
- The resultant coconut milk was left for about 24 hours to facilitate the gravitational separation of the emulsion as previously described by [27,28].
- Demulsification produced layers of an aqueous phase (water) on the bottom, an emulsion phase (cream) in the middle layer and an oil phase on top as described by [28].
- The oil on top was aluminum chloride opened and heated for about 5 minutes to remove moisture.

The obtained VCO was filtered through a fine sieve, stored at room temperature and used for the experiment.

2.5 Measurements

The body weights of the animals were measured at the end of every week throughout the period of administration using a weighing balance. Glucose test was also conducted every Friday using a glucometer, small blood from the tip of the rat's tail and a test strip to ascertain the changes in the blood glucose level before after the administration of STZ to check if type 2 diabetes is present.

2.6 Neurobehavioural Studies

2.6.1 Barnes maze

Barnes maze is a psychological laboratory experimental tool used for measuring spatial learning and memory [30]. The function of a Barnes maze is to measure the ability of a rat to learn and remember the location of distal visual cues located around the testing is [29].

2.6.2 The plan for the Barnes' maze was as follows

- Day 1: this day was used to make the Wistar rat to become familiar with the maze and to make it have an idea of what it entails.
- Day 2: training day 1, on this day a pelleted feed was kept in one of the holes and the rats were trained on how to find the box with the feed in it.
- Day 3: training day 2, this day was used for training but the animals were given a chance to find the box with the feed on their own, each rat was allowed to try severely until it could find the box with the feed.
- Day 4: this day was used to rest from the activity
- Day 5: this day was used as the probe day, the rats weren't fed throughout and then they were placed on the Barnes maze and was watched closely to see if they will be able to locate the box with feed in it.

During this examination, the amount of seconds or minutes it took for the rats to locate the box with the feed, number of errors poked, primary and total latency were measured.

2.7 Animal Sacrifice

At the end of the administration, animals were sacrificed by cervical dislocation,

the head of the animal was cut open and brain removed. Prefrontal cortex was carefully dissected and fixed in 10% formal saline for histological analysis using:

1. Haematoxylin and Eosin stain for general histoarchitecture of the animal prefrontal cortex.
2. Cresyl fast Violet stains for Nissl substance.

3. RESULTS

3.1 Results on Weights Measured

During this research experiment, the weights of the animals were weighed weekly. The Fig. 1 shows the average weight of the

animals per group during the experimental period.

3.2 Results from the Barnes Maze

Multiple comparisons were done between the primary latency travelled in Barnes maze $P = 0.05$ the primary latency of Virgin coconut oil VCO (3.60 ± 0.40) showed no significant difference when compared to control group (3.80 ± 0.37), there was a significant difference when diabetes Mellitus group DM (33.60 ± 39.4) was compared to control group (3.80 ± 0.37) there was no significant difference when treatment group (DM + VCO) (8.40 ± 1.91) was compared with the control group (3.80 ± 0.37), there was a significant difference when treatment group (DM + VCO) (8.40 ± 1.91) was compared with diabetes Mellitus group DM (33.60 ± 39.4).

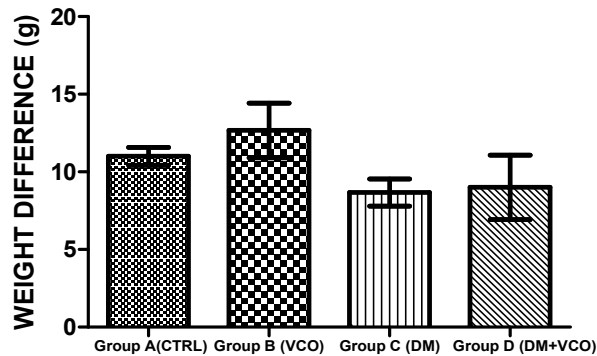


Fig. 1. Showing weight of the animals in different groups

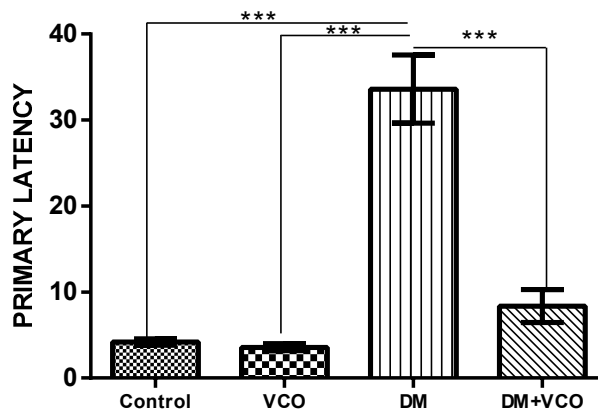


Fig. 2. Chart showing the primary latency period of experimental animals in the Barnes maze
Group A (control), Group B (VCO), Group C (dm), Group D (dm+vco)

3.3 Histology Results

Histological analysis was carried out on each group with the application of histological stains at various magnifications, results were thus shown below:

Plate 1: Photomicrographs showing panoramic views of prefrontal cortex general histomorphology

Plate 1.1: Photomicrographs showing panoramic views of prefrontal cortex general histomorphology

Plate 2: Photomicrographs showing Nissl profiles of prefrontal cortex general histomorphology

4. DISCUSSION

In this research high-fat diet and streptozotocin was used to induce type 2 diabetes mellitus and virgin coconut oil was used as treatment. During

this research weights of the animals were measured, Barnes maze was conducted as to test for cognitive function and histological analysis was also done.

Diabetes mellitus group lost a significant amount of weight, this result affirms that DM is associated with loss of weight, during diabetes there is a decrease in body weight as a result of the altered metabolic function as supported by Savitha et al. [30]. But in the Virgin Coconut oil group, the animals added a significant amount of weight which suggests that VCO helps improve appetite. The diabetes mellitus group had the highest latency in the Barnes maze test, this suggests that they had a poor memory of the activity, while the Virgin Coconut Oil group had the lowest primary latency which affirms that virgin coconut oil enhances cognitive function. In the treatment group (dm +vco) the primary latency period was significantly reduced when compared to the dm group, this

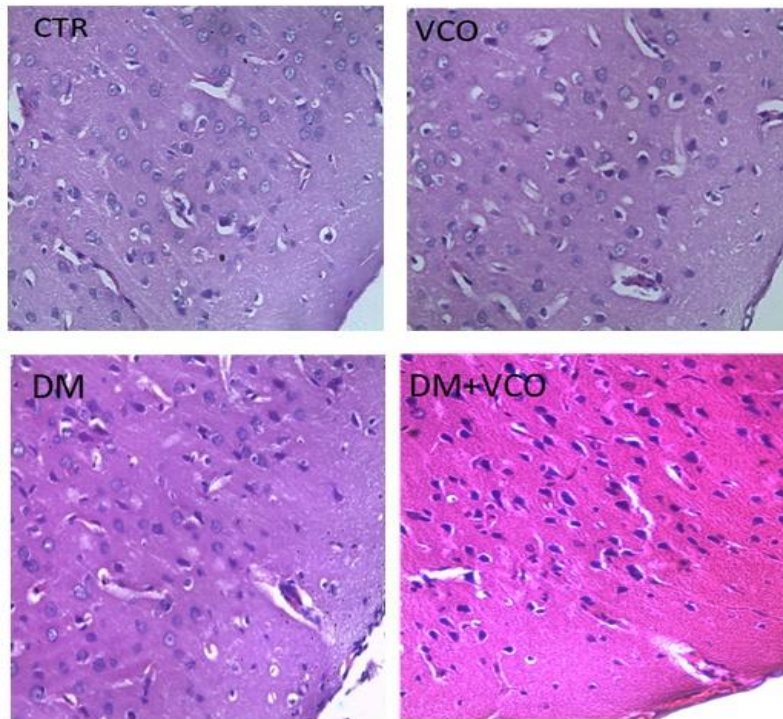


Plate 1. Photomicrographs showing panoramic views of prefrontal cortex general histomorphological presentations in Wistar rats across the study groups. Hematoxylin and Eosin stain (X100). The molecular layer (I), External granular layer (II), External pyramidal layer (III), internal granular layer (IV) are demonstrated across study groups.

Group A: control group

Group B: virgin coconut oil group (VCO)

Group C: Diabetes Mellitus group (DM) administered high-fat diet and streptozotocin

Group D: Diabetes Mellitus group (DM) administered high-fat diet and streptozotocin and virgin coconut oil group (VCO)

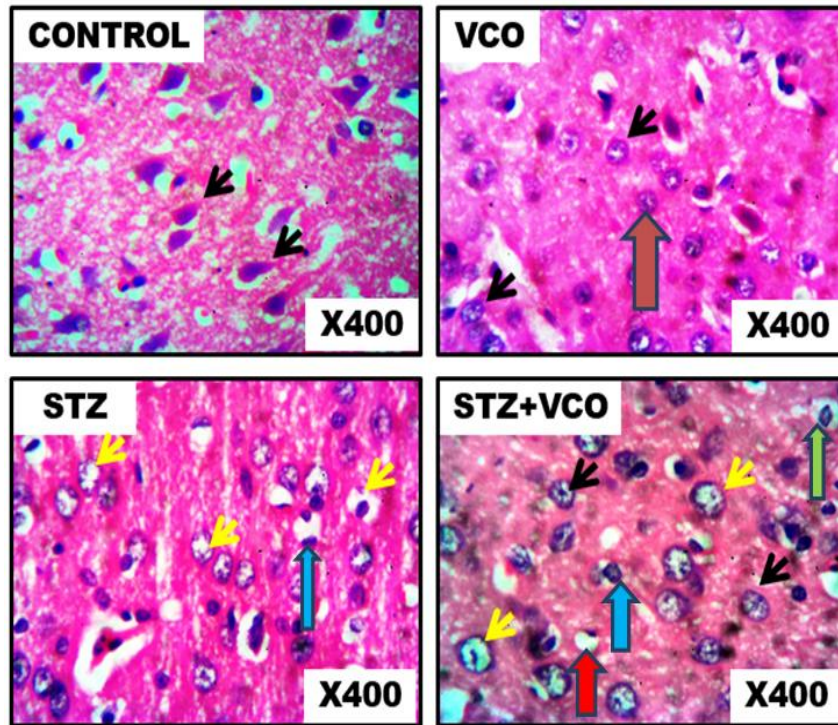


Plate 1.1. Photomicrographs showing panoramic views of prefrontal cortex general histomorphological presentations in Wistar rats across the study groups. Hematoxylin and Eosin stain (X400). The Control and VCO groups (Group A & B) present normal neurons and glia cell without any mechanical assault (Black and Red arrows). Group C (STZ or DM) present neuronal degeneration or assault as represented by Pyknosis (Blue arrow) and Vacuolation (yellow arrow) Group D (STZ + VCO) present some normal neuron and glia cells (Black and green arrows) as well as abnormal or assaulted neurons and glia cells (Red and Blue arrows).

Group A: control group

Group B: virgin coconut oil group (VCO)

Group C: Diabetes Mellitus group (DM) administered high-fat diet and streptozotocin

Group D: Diabetes Mellitus group (DM) administered high-fat diet and streptozotocin and virgin coconut oil group (VCO)

Plate 1. Photomicrographs of Prefrontal cortex of Rat stain with H&E

suggests that vco helps to improve the impaired memory and cognitive function in type 2 diabetes mellitus.

The histology of the prefrontal cortex of each group was examined using two stains: the H&E stain, and cresyl violet stain.

Normal histological features of the Control and VCO treated groups did not show any observable altered panoramic morphological presentation of the PFC layers (black arrows). From this study across the various exposures and magnification, the well-outlined array of cells within the PFC can be observed distinctly arranged from the Layer I-IV. In addition, cellular density within these

groups appears normal across all the cortical layers with appreciable spines and neuronal projections (black arrows). STZ induced degenerative changes in the cortex and was characterized by fragmented pyramidal and granule cell layer with observable pyknotic cells (yellow arrows). Also, there appeared to be a comparatively increased cell density in the cortical layers of these treated groups. VCO treatments showed slight degenerative changes (yellow arrows) mildly similar to the morphologic appearance of STZ treatments; their cortical layers seem better structured and delineated with a distinct layering when compared with STZ groups.

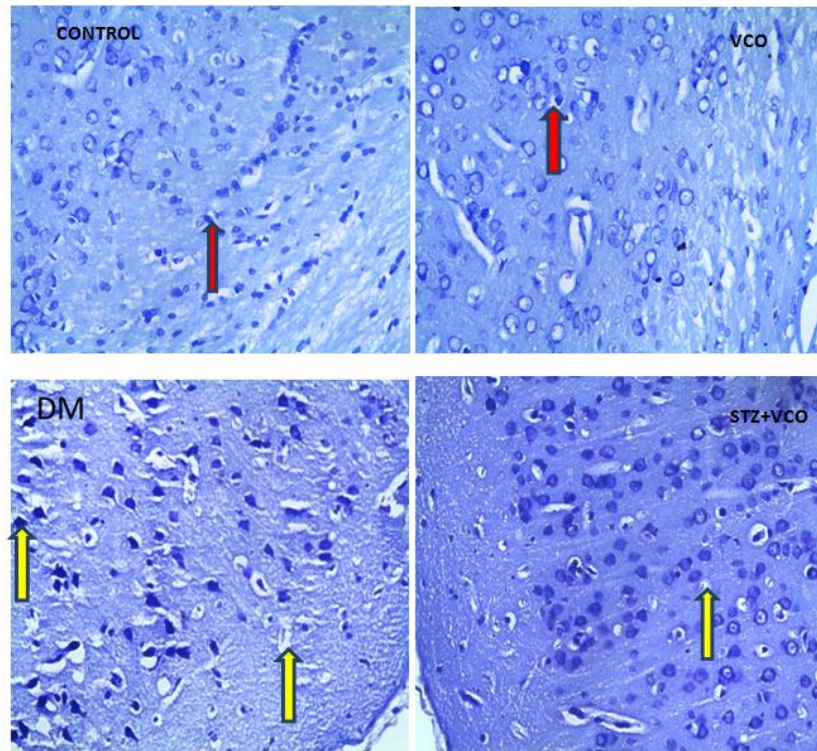


Plate 2. Photomicrographs showing Nissl profiles of prefrontal cortex general histomorphological presentations in Wistar rats across the study groups. Cresyl fast violet stains (X100). The Control and VCO group (Group A&B) presented normal nissl profiles (Red arrows). Group C (group STZ or DM) showed serious loss of nissl substance (Yellow arrows) while Group D (STZ + VCO) showed moderate or fewer loss of nissl substance (Yellow arrow)

Group A: control group

Group B: virgin coconut oil group (VCO)

Group C: Diabetes Mellitus group (DM) administered high-fat diet and streptozotocin

Group D: Diabetes Mellitus group (DM) administered high-fat diet and streptozotocin and virgin coconut oil group (VCO)

Also, Nissl profile demonstration by CFV stain (X100) across PFC sections within the study groups shows poor staining outcome in the untreated STZ-induced diabetic rats compared with the control. The weak staining characteristic of the prefrontal pyramidal cells in these diabetic rats suggests loss or reduction of Nissl bodies of these cells; normal morphological presentations in CONTROL and VCO treatments that are characterized with normal and densely populated Nissl proteins, well stained and outlined neurons (Red arrows). STZ caused severe chromatolytic changes as well as some pyknotic changes in both the pyramidal and granule cell layers with a gross reduction in the cytoplasmic Nissl proteins (yellow arrows). And this implies decreased the synthetic activity of the pyramidal neurons, with possible impairment of cognitive function in these animals.

5. CONCLUSION

Diabetes affected the prefrontal cortex negatively while virgin coconut oil seems to neutralize the adverse effect and tried to restore the integrity of the prefrontal cortex. VCO has the potential to be used as a memory enhancer, the effect of which was mediated, at least in part, through enhanced cholinergic activity, increased antioxidants level and reduced oxidative stress.

CONSENT

It is not applicable.

ETHICAL APPROVAL

The study was done in Babcock University and approved by the Babcock University Ethics

commission (BUHREC). The experiment took the total of 45 days.

COMPETING INTERESTS

Authors have declared that no competing interests exist.

REFERENCES

1. World Health Organization, a global report on Diabetes. Accessed 30 September 2016.
2. Hassing L, Grant MS, Hofer. Type 2 diabetes mellitus contributes to cognitive decline in old age: A longitudinal population-based study. *J. Intl. Neuropsychol. Soc.* 2004;10:599–607.
3. Hayashi K, Kojima R, Ito M. Strain differences in the diabetogenic activity of streptozotocin in mice. *Biol Pharm Bull.* 2006;29:1110–1119.
4. Patlak M. New weapons to combat an ancient disease: Treating diabetes. *Faseb J Dec.* 2002;16(14):1853.
5. Maitra A, Abbas AK. Endocrine system. In: Kumar V, Fausto N, Abbas AK (eds), Robbins and Cotran Pathologic basis of disease (7th ed) Philadelphia, Saunders; 2005;1156-1226.
6. Lebovitz HE, Banerji MA. Treatment of insulin resistance in Diabetes mellitus. *Eur. J. Pharmacol.* 2004;490:135–146.
7. Kidd PM. Alzheimer's disease, amnesic mild cognitive impairment, and age-associated memory impairment: current understanding and progress toward integrative prevention. *Alternative Medicine Review: A Journal of Clinical Therapeutic.* 2008;13:85-115
8. Luchsinger JA, Reitz C, Patel B, Tang MX, Manly JJ, Mayeux R. Relation of diabetes to mild cognitive impairment. *Archives of Neurology.* 2007;64:570-575.
9. Heistad Donald D. Oxidative stress and vascular disease. *Arterioscler Thromb Vasc Biol.* 2005;26:689–95.
10. Pham-Huy LA, He H, Pham-Huy C. Free radicals, antioxidants in disease and health. *IJBS.* 2008;4(2):89–96.
11. Moussa SA. Oxidative stress in diabetes mellitus. *Romanian J. Biophys.* 2008;18(3): 225–236.
12. Jurado MB, Rosselli M. The elusive nature of executive functions: A review of our current understanding. *Neuropsychology Review.* 2007;17:213–233.
13. McCrimmon RJ, Ryan CM, Frier BM. Diabetes and cognitive dysfunction. *Lancet.* 2012;379:2291-2299.
14. Roberts RO, Geda YE, Knopman DS, Christianson TJ, Pankratz VS, Boeve BF, Vella A, Rocca WA, Petersen RC. Association of duration and severity of diabetes mellitus with mild cognitive impairment. *Arch Neurol.* 2008;65:1066-1073.
15. Zhao WQ, Alkon DL. Role of insulin and insulin receptor in learning and memory. *Molecular and Cellular Endocrinology.* 2001;177:125-134.
16. Derakhshan F, Toth C. Insulin and the brain. *Current Diabetes Reviews.* 2013;9: 102-116.
17. Moran C, Phan TG, Chen J, et al. Brain atrophy in type 2 diabetes regional distribution and influence on cognition. *Diab. Care.* 2013;36:4036–4042.
18. Den Heijer T, Vermeer SE, van Dijk EJ, et al. Type 2 diabetes and atrophy of medial temporal lobe structures on brain MRI. *Diabetologia.* 2003;46:1604–1610.
19. Brundel M, van den Heuvel M, de Bresser J, et al. Cerebral cortical thickness in patients with type 2 diabetes. *J. Neurol. Sci.* 2010;299:126–130.
20. Manschot SM, Biessels GJ, de Valk H, et al. Metabolic and vascular determinants of impaired cognitive performance and abnormalities on brain magnetic resonance imaging in patients with type 2 diabetes. *Diabetologia.* 2007;50:2388–2397.
21. Assunção ML. Effects of dietary coconut oil on the biochemical and anthropometric profiles of women presenting abdominal obesity. *Lipids.* 2009;44:593–601. Available:<http://doi.org/10.1007/s11745-009-3306-6>
22. Ohkawa H, Ohishi N, Yagi K. Assay of lipid peroxidation in animal tissue by thiobarbutyric acid reaction. *Analytical Biochemistry.* 1979;95:351-358.
23. Maritim AC, Sanders RA, Watkins JB. Diabetes, oxidative stress and antioxidants: A review. *Journal of Biochemical and Molecular Toxicology.* 2003;17:24-38.
24. Borenshtein DR, Ofri M, Werman A, Stark HJ, Tritschler W, Moeller Madar Z. Cataract development in diabetic sand rats treated with alpha-lipoic acid and its gamma-linolenic acid conjugate. *Diabetes/ Metabolism Research and Reviews.* 2001;17:44-50.

25. Nevin KG, Rajamohan T. Virgin coconut oil supplemented diet increases the antioxidant status in rats. *Food Chem.* 2006;99:260-266.
26. Nevin KG, Rajamohan T. Beneficial effects of virgin coconut oil on lipid parameters and in vitro LDL oxidation. *Clinical Biochemistry.* 2004;37(9):830-835.
27. Onsaard E, Vittayanont M, Srigam S, McClements DJ. Properties and stability of oil-in-water emulsions stabilized by coconut skim milk proteins. *Journal of Agriculture and Food Chemistry.* 2005;53: 5747.
28. Nour AH, Mohammed FS, Yunus RM, Arman A. Demulsification of virgin coconut oil by centrifugation method: A feasibility study. *International Journal of Chemical Technology.* 2009;1(2):59.
29. Barnes CA. Memory deficits associated with senescence: A neurophysiological and behavioral study in the rat. *J Comp Physiol Psychol.* 1979;93(1):74-104.
30. Savitha B, Peeyush Kumar T, Paulose CS. Glutamate (mGluR-5) "gene expression in brain regions of streptozotocin induced diabetic rats as a function of age: role in regulation of calcium release from the pancreatic islets in vitro. *Journal of Biomedical Science.* 2009;16:99:5-11.

© 2017 Olanrewaju et al.; This is an Open Access article distributed under the terms of the Creative Commons Attribution License (<http://creativecommons.org/licenses/by/4.0>), which permits unrestricted use, distribution, and reproduction in any medium, provided the original work is properly cited.

Peer-review history:

The peer review history for this paper can be accessed here:

<http://www.sciencedomain.org/review-history/23448>