



Research Article

Effects of Carob (*Ceratonia siliqua*) on Sperm Quality, Testicular Structure, Testosterone Level and Oxidative Stress in Busulfan-Induced Infertile Mice

Azadeh Vafaei¹, Shabnam Mohammadi^{2*}, Alireza Fazel¹, Mohammad Soukhtanloo³, Abbas Mohammadi pour¹, Farimah Beheshti⁴

¹Department of Anatomy and Cell Biology, School of Medicine, Mashhad University of Medical Sciences, Mashhad, Iran.

²Neurogenic Inflammation Research Center, Mashhad University of Medical Sciences, Mashhad, Iran.

³Department of Clinical Biochemistry, School of Medicine, Mashhad University of Medical Sciences, Mashhad, Iran.

⁴Department of Physiology, School of Medicine, Mashhad University of Medical Sciences, Mashhad, Iran.

Article Info

Article History:

Received: 9 October 2017

Revised: 6 February 2018

Accepted: 9 February 2018

ePublished: 20 June 2018

Keywords:

-Carob
-Mice. Spermatozoa
-Testis
-Busulfan

ABSTRACT

Background: *Ceratonia siliqua* has antioxidant activities that may inactivate toxic factors and influence sperm quality. To the best of the authors' knowledge, there is no available data on the effects of carob on male fertility. Hence, the purpose of this study was to investigate the effects of carob on sperm quality, testicular structure, and level of testosterone hormone in busulfan-induced infertile mice.

Methods: Sixty-four adult male mice were randomly divided into 8 groups (control, sham, busulfan and carobs 1 to 5). The busulfan group was injected a single dose of 10 mg/kg busulfan intraperitoneally. Carobs 1 to 5 groups received intraperitoneal doses of 800, 400, 200, 100 and 50 mg/kg of carob extract plus a single dose of 10 mg/kg busulfan for 35 days. The sperm analysis, morphometric study, testosterone levels and oxidative stress determination were done on the 35th day of the experiment.

Results: The lowest percentage of sperm parameters was related to the busulfan group and the highest was related to the carobs 1 and 2 groups. The seminal vesicles index of the carob 1 group showed a significant increase as compared to the busulfan group ($p < 0.001$). A significant increase was observed in the mean value of germinal epithelium thickness, as well as thiol and catalase levels in carobs 1 and 2 groups as compared to the busulfan group ($p < 0.001$). There was a significant increase in the mean level of testosterone in the carob groups as compared to the busulfan group ($p < 0.001$). Also, there was a significant decrease in the mean value of malondialdehyde level in the carobs 1 and 2 groups $p < 0.001$ and a significant increase in the mean value of superoxide dismutase enzyme in the carob groups as compared to the busulfan group ($p < 0.001$).

Conclusion: Administration of 800 mg/kg of carob extract for 35 days improved sperm quality, biochemical parameters, thickness of germinal epithelium and testosterone levels in infertile mice induced by busulfan.

Introduction

Several factors such as drugs, toxic substances and infection lead to infertility in men. Some medications like busulfan have toxic effects on the reproductive system.¹ Busulfan is one of the chemotherapeutic agents that widely used in the treatment of various cancers, leukemia, malignant lymphomas and autoimmune diseases.¹ Despite the many clinical applications of busulfan, it has most important complications which are spermatogenesis disorder and infertility.²⁻⁵ Therefore, injections of various busulfan dosages are used for induction of infertility in animal models.²⁻⁵ On the other hand, the administration of medicinal herbs with little side effects has a long history in treatment of infertility. Evidences show herbs such as

ginseng, ginger, black seed and saffron are effective on male fertility.⁶

Ceratonia siliqua (carob) is a species of Bacchillas (medicinal plant), with the exception of evergreen trees with a height of 12-17 m. Carob is grown extensively in Italy, Spain and Turkey. It is also grown in Fars and Kazeroun, two cities of Iran. About 40% of it is carbohydrate with a simple molecular structure. Its fat content is about 1% and its protein is 3 to 4%. Besides, it contains a lot of fiber, minerals such as potassium, sodium, calcium, iron and phosphorus, as well as vitamins E, D, C, B6, niacin, folic acid and polyphenol.⁷⁻⁹ Studies have shown that carob administration protects against the harmful effects of alcohol in the gastrointestinal tract.⁹ Besides, this plant has anti-bacterial,¹⁰ anti-cancer,¹¹ anti-

*Corresponding Author: Shabnam Mohammadi, E-mail: mohammadish@mums.ac.ir

©2018 The Authors. This is an open access article and applies the Creative Commons Attribution (CC BY), which permits unrestricted use, distribution, and reproduction in any medium, as long as the original authors and source are cited. No permission is required from the authors or the publishers.

diabetic¹² and strong antioxidant properties.⁸ Considering that in some areas, it has been shown that carob has a positive effect on male fertility and spermatogenesis, and based on the authors' search showing that there is no available study on the effects of carob on spermatogenesis, the aim of the present study was to evaluate the effects of carob extract on spermatogenesis, testicular structure and testosterone hormone in busulfan-induced infertile mice.

Materials and Methods

Experimental groups

This experimental study was performed on 64 adult Balb/c male mice after approval by the Ethics Committee of Mashhad University of Medical Sciences (code 941194). The mice were kept under standard conditions in animal house of Mashhad University of Medical Sciences, then, randomly divided into 8 groups. The control group did not receive injections. The busulfan group was injected a single dose of 10 mg/kg busulfan (Sigma, Germany) intraperitoneally. The sham group received busulfan solution by intraperitoneal injection. Carobs 1 to 5 groups received intraperitoneal doses of 800, 400, 200, 100 and 50 mg/kg of carob extract, respectively, plus a single dose of 10 mg/kg busulfan for 35 days (due to the duration of spermatogenesis in mice).

Carob extract preparation

The carob was confirmed by the Department of Botany, Mashhad University. 100 g of dried carob powder was added to 1000 cc distilled water. It was then placed in a shaker for 24 h at room temperature. Then, a Whatman No. 1 filter was passed and concentrated in a 40°C bathwater to slowly evaporate the extract water. This extract was dissolved in saline and injected intraperitoneally into animals.

Sperm analysis

After 35 days, the mice were anesthetized with chloroform solution and pieces of epididymis were placed in normal saline in a CO₂ incubator. Sperms were examined according to the WHO guidelines. To determine the viability of sperm, 20 µl of sperm solution and 10 µl of Eosin B were mixed on a glass slide and was examined using the microscope.¹³

Measurement of germinal epithelium thickness

Routine histological examination was performed for right testes and was stained with hematoxylin-eosin. The slides were then viewed shot at 10 × magnification and the average thickness of the germinal epithelium was calculated according to the following formula:¹⁴⁻¹⁷

$$H = \frac{V_v}{S_v}$$

$$V_v = \frac{\sum_{i=1}^n P(x)}{\sum_{i=1}^n P(\text{total})}$$

$$S_v = 2 \times \frac{\sum_{i=1}^n l_i}{l/p \times \sum_{i=1}^n P_i}$$

H: height of epithelium, S_v: surface density, V_v: surface

density, ΣT: total points of collisions of probe lines with the lumen of the germinal epithelium, Σp: total points of contact, ΣI with testicular tissue and l/p length of probe line on the actual scale of the tissue.

Measurement of testosterone hormone

Blood samples obtained from the heart were centrifugal at 2000 rpm for 5 min. Testosterone levels was measured using ELISA method (Elsys 2010, England) and the electrochemiluminescence (ECL) tests were randomized for control results.¹⁸

Measurement of thiol level

Fifty microliter of homogenized solution of testis tissue was mixed with TRIS buffer and absorption was read at 412 nm using a spectrophotometer (A1). Ellman's reagent was added and after 15 min incubation at room temperature, the absorption was read again (A2). Blank absorption was considered as B. The concentration of thiol was calculated based on the following formula:¹⁹

$$(A2-A1-B) \times 1.07 / 0.05 \times 13.6$$

Measurement of malondialdehyde level

Homogenized testis tissue solution was mixed with trichloroacetic acid, hydrogen chloride and was placed in a boiling water bath for 45 min. After cooling, it was centrifuged at 1000 rpm for 10 min and absorption was read at 535 nm by spectrophotometer.¹⁹

Measuring superoxide dismutase and catalase enzymes

For measurement of superoxide dismutase enzyme, the Madesh Balasubramanain method was used. After adding hydrogen peroxide to the tissue sample, the absorbance was read at 570 nm in contrast to the blank expressed as U/g.²⁰ The catalase enzyme was measured after adding hydrogen peroxide to the tissue sample, its absorption was read at 240 nm and expressed in U/g.¹⁸

Statistical analysis

Data were expressed as mean ± standard deviation and percentages, and analyses were performed using the SPSS software, ANOVA and Tukey post hoc test.

Results

Sperm analysis

As shown in Table 1, the lowest percentage of sperm motility was related to busulfan group (50.24%) and the highest was observed in carob1 group (63.36%). The highest percentage of sperm viability (77.56%) and sperm morphology rate (78.08%) was related to carob 2 group. Statistical analysis did not show a significant difference between the sperm count of experimental groups (p > 0.05). There was a significant difference between the normal morphology rate, viability and motility of sperm in carobs 1 to 5 groups and busulfan group as compared to the control group (p < 0.001). In addition, there was a significant increase in the normal morphology rate of sperm in the carob 2 group (p < 0.001) as compared to the busulfan group. There was a significant increase in sperm

viability of carobs 1 ($p < 0.001$), 2 ($p < 0.001$), 3 ($p < 0.001$), and 4 groups ($p < 0.001$) as compared to the busulfan group. Besides, there was a significant increase

in sperm motility between carobs 1 group ($p < 0.001$), 2 ($p < 0.001$), 3 ($p = 0.001$), 4 ($p = 0.004$) and 5 groups ($p = 0.013$) as compared to the busulfan group.

Table 1. Sperm parameters in different experimental groups.

Group	Sperm count (million/ ml)	Normal morphology rate (%)	Viability rate (%)	Motility rate (%)
Control	4.54 ± 0.55	88.35 ± 7.31#	89.05 ± 6.78#	79.84 ± 9.57#
Sham	4.34 ± 0.71	84.75 ± 8.00#	85.51 ± 10.03#	78.36 ± 11.48#
Busulfan	3.04 ± 0.55	68.28 ± 8.19*	59.92 ± 6.38*	50.24 ± 9.30*
Carob 1	4.04 ± 0.48#	72.32 ± 20.01*	73.00 ± 8.41*#	63.36 ± 9.77*#
Carob 2	4.13 ± 0.32	78.08 ± 5.53#*	77.56 ± 4.42*#	63.20 ± 9.05*#
Carob 3	3.74 ± 0.39	70.68 ± 6.32*	71.64 ± 7.51*#	60.92 ± 7.81*#
Carob 4	3.88 ± 0.33	74.56 ± 7.53*	77.00 ± 3.59*#	59.92 ± 6.51*#
Carob 5	3.00 ± 0.69	69.72 ± 6.25*	65.4 ± 9.71*	59.00 ± 5.72*#

* Significant difference with control group in same column by ANOVA and Tukey post-hoc test.

Significant difference with busulfan group in same column by ANOVA and Tukey post-hoc test.

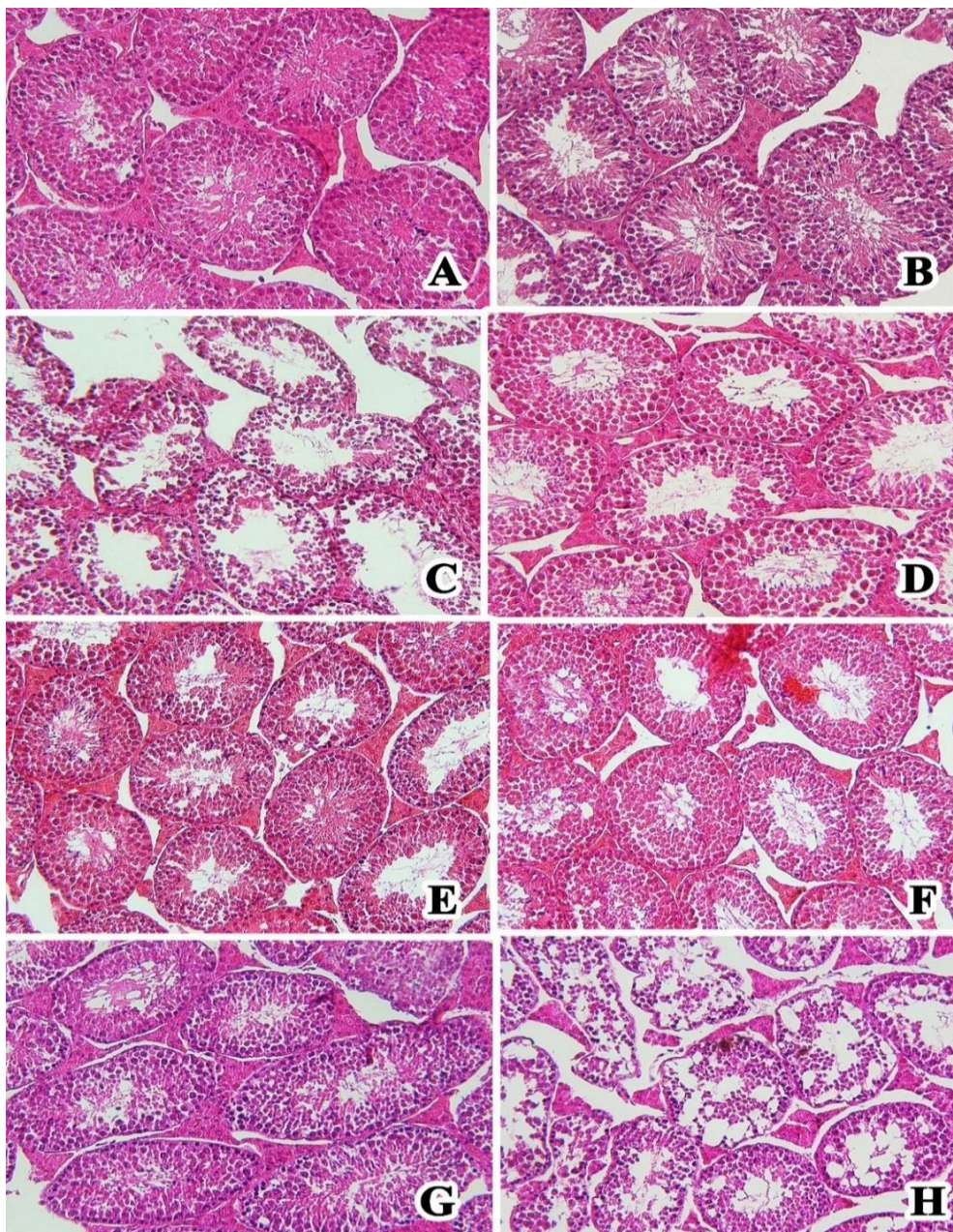


Figure 1. Images (A-H) show section of seminiferous tubules in the control, sham, carob 1- carob 5 groups, busulfan. They are stained with hematoxylin-eosin and magnification is 200 ×

Table 2. Effect of Carob extract on thickness of germinal epithelium in different experimental groups.

Experimental groups	Thickness of germinal epithelium (μm)
Control	62.00 \pm 4.81 ^{#*}
Sham	57.00 \pm 10.58*
Busulfan	39.66 \pm 3.38*
Carob 1	61.79 \pm 5.00
Carob 2	59.32 \pm 4.10 ^{#*}
Carob 3	44.56 \pm 9.52*
Carob 4	48.80 \pm 9.17
Carob 5	39.79 \pm 8.38*

* Significant difference with Carob1 in same column by ANOVA and Tukey post-hoc test.

Significant difference with Carob3 in same column by ANOVA and Tukey post-hoc test.

x Significant difference with busulfan group in same column by ANOVA and Tukey post-hoc test.

Morphometric results

As shown in Table 2, the thickness of germinal epithelium in the busulfan group decreased as compared to the control group ($P = 0.000$). Among the groups that received carob extract, the highest mean value of germinal epithelium thickness was observed in carob 1 group and the lowest was found in carob 5 group. There was a significant increase between carobs 1 ($p = 0.000$) and 2 groups ($p = 0.001$) as compared to the busulfan group (Figure 1).

Measurement of Testosterone level

As shown in Figure 2, the mean value of testosterone level was significantly different in the busulfan ($p < 0.001$),

carobs 1 ($p < 0.001$), 2 ($p = 0.037$) and 5 groups ($p < 0.001$) as compared to the control group. There was a significant increase between the mean value of testosterone hormone in the carob 1 ($p < 0.000$), 2 ($p < 0.000$), 3 ($p < 0.000$), 4 ($p < 0.000$), and 5 groups ($p = 0.006$) as compared to the busulfan group.

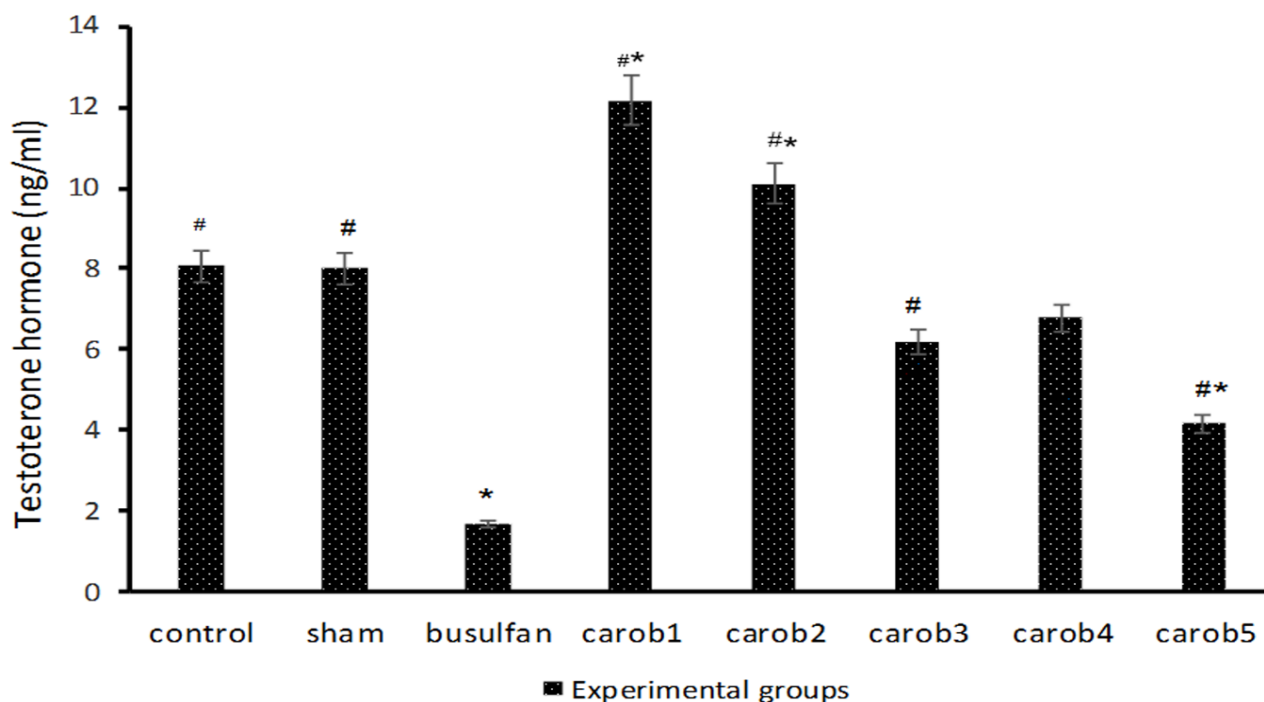
Measurement of thiol and malondialdehyde level

There was a significant difference between the mean level of thiol in the busulfan group ($p < 0.001$), carobs 2 ($p = 0.003$), 3 ($p < 0.001$), 4 ($p < 0.001$) and 5 groups ($p < 0.001$) as compared to the control group. Significant decrease was observed between the mean level of thiol in carobs 1 ($p < 0.001$) and 2 groups ($p < 0.001$) as compared to the busulfan group (Figure 3).

Figure 4 shows malondialdehyde level in testes of experimental groups. Significant increase was observed between the mean level of malondialdehyde in carobs 1 ($p < 0.001$) and 2 groups ($p = 0.002$) as compared to the busulfan group.

Measurement of superoxide and catalase enzymes

Figure 5 shows the level of superoxide dismutase and catalase enzymes in the experimental groups. There was a significant increase in the mean level of superoxide dismutase in carobs 1 ($p < 0.001$), 2 ($p < 0.001$) and 3 groups ($p = 0.028$) as compared to the busulfan group. There was a significant increase in the mean level of catalase enzyme in carobs 1 and 2 groups as compared to the busulfan group ($p < 0.001$).

**Figure 2.** Testosterone levels in ng / ml in blood serum of experimental groups.

* Significant difference with control group by ANOVA and Tukey post-hoc test.

Significant difference with busulfan group by ANOVA and Tukey post-hoc test.

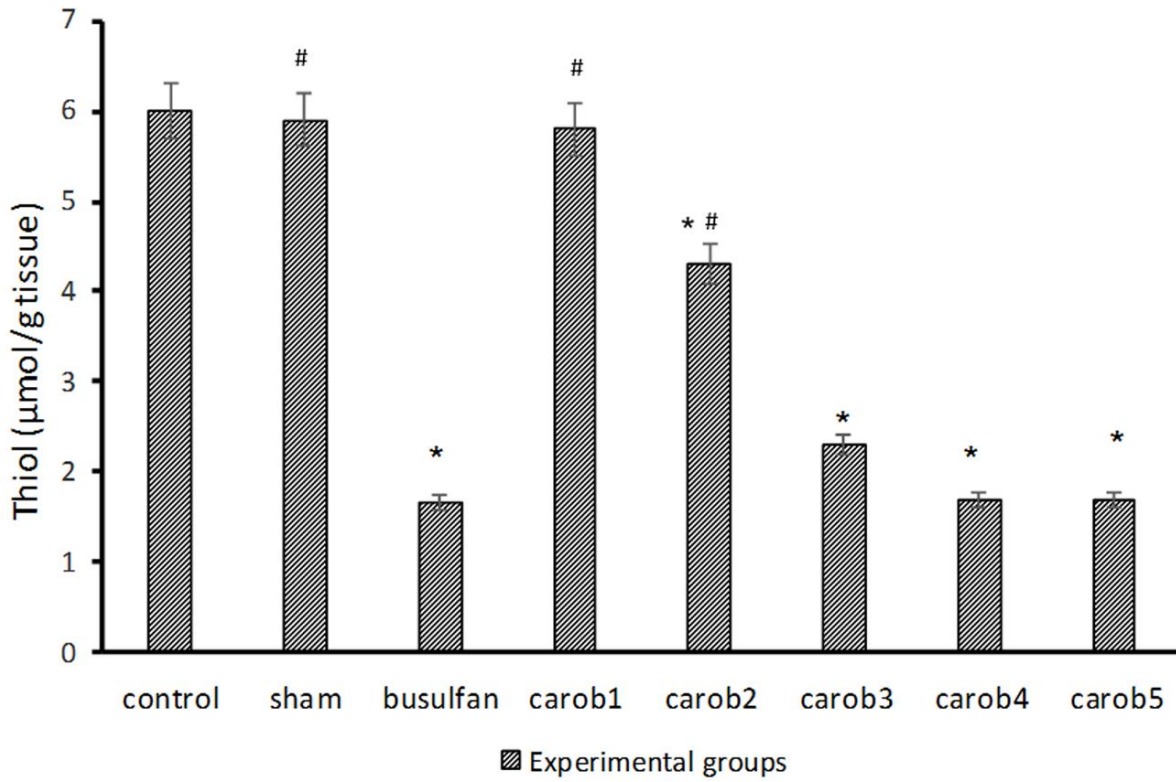


Figure 3. Thiol levels in µmol/ g tissue in the experimental groups.
 * Significant difference with control group by ANOVA and Tukey post-hoc test.
 # Significant difference with busulfan group by ANOVA and Tukey post-hoc test.

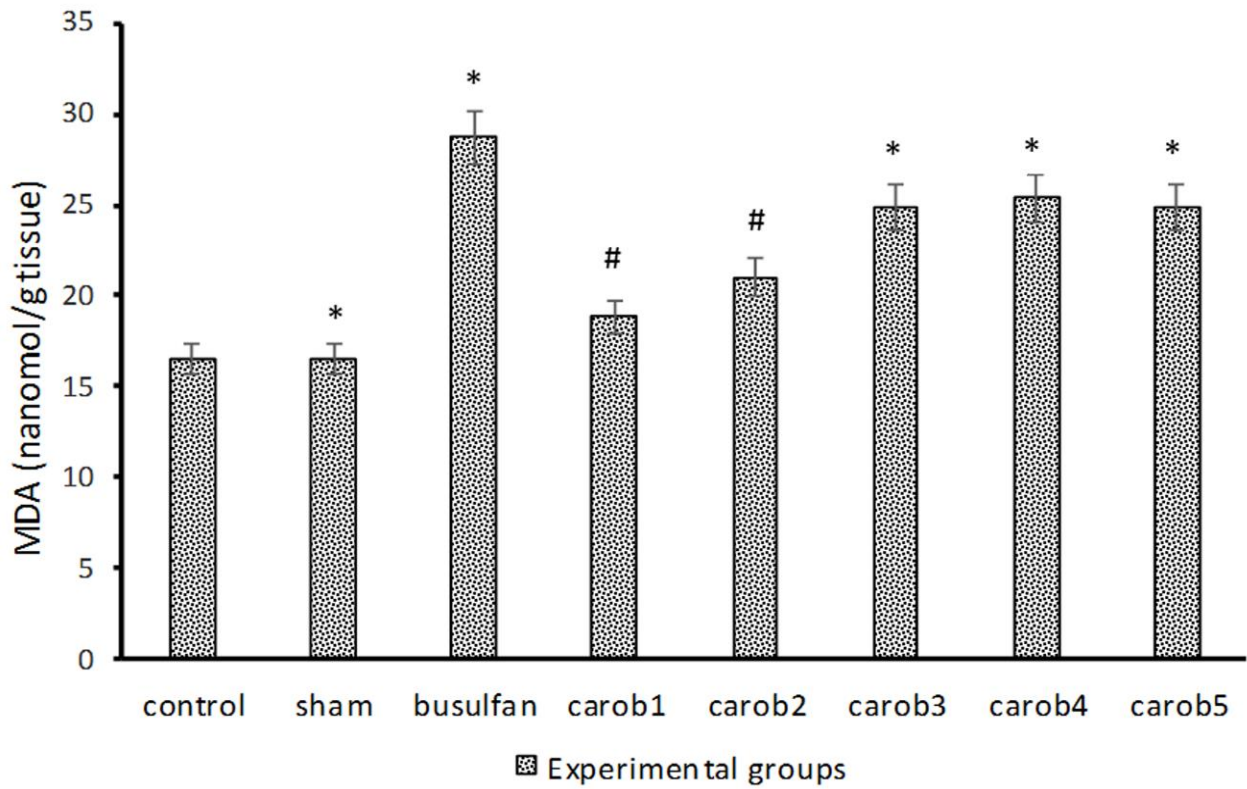


Figure 4. Malondialdehyde level in nmol / g tissue in the experimental groups.
 * Significant difference with control group by ANOVA and Tukey post-hoc test.
 # Significant difference with busulfan group by ANOVA and Tukey post-hoc test.

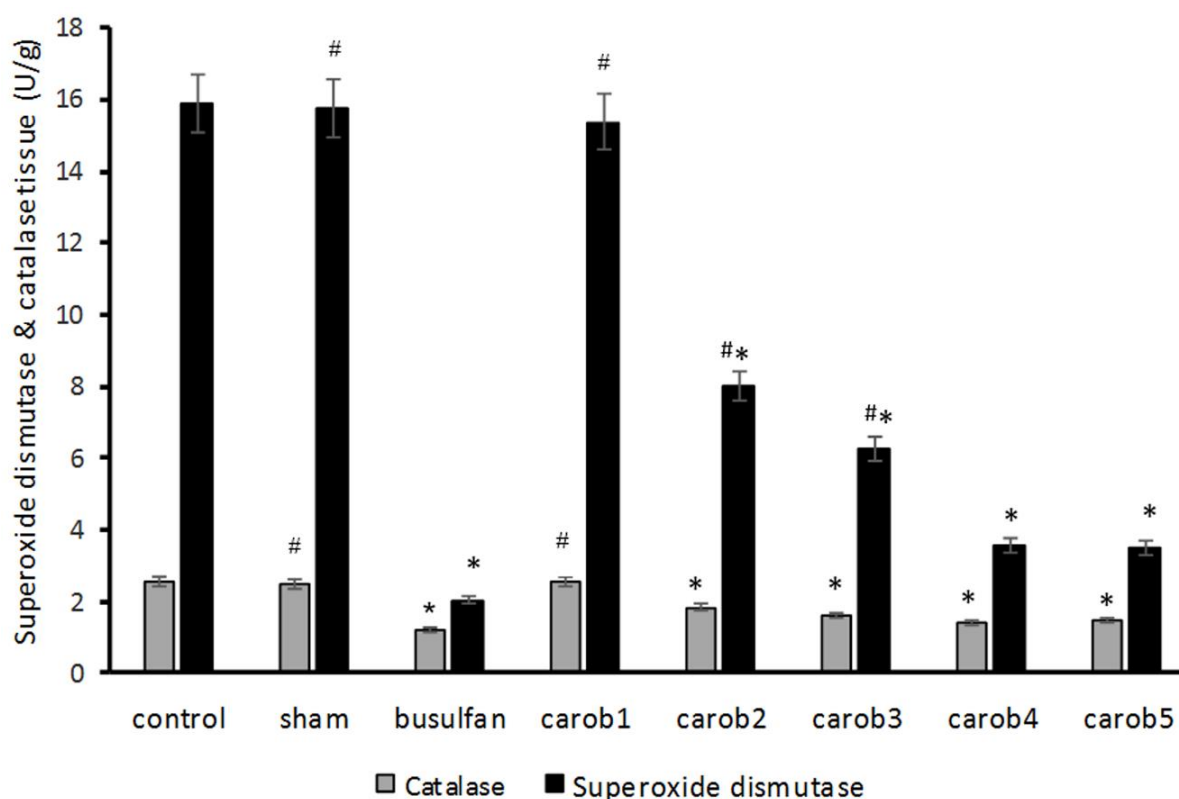


Figure 5. Level of superoxide dismutase and catalase enzymes in U / g tissue in the experimental groups.

* Significant difference with control group by ANOVA and Tukey post-hoc test.

Significant difference with busulfan group by ANOVA and Tukey post-hoc test.

Discussion

The results of this study showed that the highest rate of sperm motility was recorded for infertile mice that received 800 mg/kg of carob extract and the highest percentage of sperm viability and sperm normal morphology rate was related to infertile mice that received 400 mg/kg of carob extract. The level of superoxide dismutase enzyme was highest in the infertile mice that received 800 mg/kg of carob extract, while the level of MDA was the lowest in these mice. The thickness of germinal epithelium, and thiol and catalase levels increased in the infertile mice that received 800 and 400 mg of carob extract. Level of testosterone hormone increased in all the infertile mice that received carob extract.

Zohini et al. reported that spermatogonia cells reduced after administration of 15, 30 and 45 mg of busulfan. The testicular weight decreased by 30 to 50% based on the dose of busulfan.²¹ Bordbar and colleagues induced the infertile mice model by injection a single dose of 5 mg/kg of busulfan. They reported that busulfan reduced the volume of seminiferous tubules as well as interstitial tissue. In addition, the level of testosterone, sperm motility and count decreased in the busulfan group as compared to the control group.²²

Jung and colleagues reported that 40 mg/kg of busulfan caused injury to testicular tissue as well as reduction of sperm parameters and testosterone hormone.²³ Another study showed that busulfan administration caused a

reduction in sperm parameters and glutathione peroxidase levels as well as increase in caspase 3 and MDA level.²⁴ Dehghani et al. induced infertility rat model by injection of busulfan. Their results showed that busulfan reduced sperm count, normal morphology rate and hormone levels.²⁵ Consistent with these studies, the result of the present study showed that busulfan reduced the thickness of germinal epithelium, sperm parameters, testosterone levels and biochemical parameters.

Studies show carob extract protects the gastrointestinal tract against alcohol consumption effect.⁹ It also has antibacterial,¹⁰ anticancer,¹¹ anti-diabetic¹² and antioxidant properties.⁸ To the best of the authors' knowledge, there is no available study on the effects of carob on spermatogenesis for comparison of results. However, it has been shown that this plant has a positive effect on male fertility in some areas of Iran. In a study conducted by Souli,²⁶ the protective effect of carob extract on oxidative stress in liver induced by alcohol was investigated. The levels of malondialdehyde decreased while the level of enzyme superoxide dismutase and catalase increased in the carob group. In the present study, after administration of the carob extract, the levels of superoxide dismutase and catalase increased. These effects were dose-dependent. The effects of higher dose of carob were better than those of low dose. This shows that antioxidants are a double-edged sword; dosage and duration of administration are very important and inappropriate dosage or short-time of treatment produce a

high amount of ROS that stops the cell cycle and increase the apoptosis process.^{27, 28} The investigation of long-time effects of carob treatment on spermatogenesis as well as apoptosis in testicular tissue of adult males is suggested for future researches. Also, the effect of different dosages of carob extract on the level of testosterone hormone and histopathology of testis in adult male mice is suggested for future studies.

Conclusion

The administration of 800 mg/kg of carob extract for 35 days improved sperm quality, biochemical parameters, thickness of germinal epithelium and testosterone levels in infertile mice induced by busulfan. Considering that infertility by busulfan or chemotherapy causes a lot of problems to cancer patients who are often at the age of reproduction, carob treatment may be effective in preserve of their fertility.

Acknowledgment

This paper, derived from the master's thesis in Anatomy Sciences (code 941194), has been funded by the Vice-Chancellor of Research in Mashhad University of Medical Sciences.

Conflict of interests

The authors claim that there is no conflict of interest.

References

- Gabrielsen JS, Tanrikut C. Chronic exposures and male fertility: the impacts of environment, diet, and drug use on spermatogenesis. *Andrology*. 2016;4(4):648-61. doi:10.1111/andr.12198
- Amin A, Hamza AA. Effects of Roselle and Ginger on cisplatin-induced reproductive toxicity in rats. *Asian J Androl*. 2006;8(5):607-12. doi:10.1111/j.1745-7262.2006.00179.x
- Juenke JM, Miller KA, McMillan GA, Johnson-Davis KL. An automated method for supporting busulfan therapeutic drug monitoring. *Ther Drug Monit*. 2011;33(3):315-20. doi:10.1097/ftd.0b013e318214cd75
- Anjamrooz SH, Movahedin M, Mowla SJ, Bairanvand SP. Assessment of morphological and functional changes in the mouse testis and epididymal sperms following busulfan treatment. *Iran Biomed J*. 2007;11(1):15-22.
- Wang DZ, Zhou XH, Yuan YL, Zheng XM. Optimal dose of busulfan for depleting testicular germ cells of recipient mice before spermatogonial transplantation. *Asian J Androl*. 2010;12(2):263-70. doi:10.1038/aja.2009.67
- D'Cruz SC, Vaithinathan S, Jubendradass R, Mathur PP. Effects of plants and plant products on the testis. *Asian J Androl*. 2010;12(4):468-79. doi:10.1038/aja.2010.43
- Śęczyk Ł, Świeca M, Gawlik-Dziki U. Effect of carob (*Ceratonia siliqua* L.) flour on the antioxidant potential, nutritional quality, and sensory characteristics of fortified durum wheat pasta. *Food Chem*. 2016;194:637-42. doi:10.1016/j.foodchem.2015.08.086
- Custódio L, Escapa AL, Fernandes E, Fajardo A, Aligué R, Alberício F, et al. Phytochemical profile, antioxidant and cytotoxic activities of the carob tree (*Ceratonia siliqua* L.) germ flour extracts. *Plant Foods Hum Nutr*. 2011;66(1):78-84. doi:10.1007/s11130-011-0214-8
- Rtibi K, Jabri MA, Selmi S, Souli A, Sebai H, El-Benna J, et al. Gastroprotective effect of carob (*Ceratonia siliqua* L.) against ethanol-induced oxidative stress in rat. *BMC Complement Altern Med*. 2015;15(1):292. doi:10.1186/s12906-015-0819-9
- Meziani S, Oomah BD, Zaidi F, Simon-Levert A, Bertrand C, Zaidi-Yahiaoui R. Antibacterial activity of carob (*Ceratonia siliqua* L.) extracts against phytopathogenic bacteria *Pectobacterium atrosepticum*. *Microb Pathog*. 2015;78:95-102. doi:10.1016/j.micpath.2014.12.001
- Corsi L, Avallone R, Cosenza F, Farina F, Baraldi C, Baraldi M. Antiproliferative effects of *Ceratonia siliqua* L. on mouse hepatocellular carcinoma cell line. *Fitoterapia*. 2002;73(7-8):674-84. doi:10.1016/s0367-326x(02)00227-7
- Rtibi K, Selmi S, Grami D, Saidani K, Sebai H, Amri M, et al. *Ceratonia siliqua* L. (immature carob bean) inhibits intestinal glucose absorption, improves glucose tolerance and protects against alloxan-induced diabetes in rat. *J Sci Food Agric*. 2017;97(8):2664-70. doi:10.1002/jsfa.8091
- Mohammadi S. Protective Effect of N-Acetyl Cysteine Against Formaldehyde-Induced Neuronal Damage in Cerebellum of Mice. *Pharm Sci*. 2014;20(2):61-5.
- Mohammadi S, Golamin M, Mohammadi M, Mansouri A, Mahmoodian R, Attari S, et al. Down-regulation of CatSper 1 and CatSper 2 genes by lead and mercury. *Environ Toxicol Pharmacol*. 2018; 59:82-6. doi:10.1016/j.etap.2018.03.007
- Mohammadi S, Pakrouh Z, Teimouri M, Hagi Pour S, Karimi M, Mohammadi M, et al. Effects of drug substance crystal (methamphetamine) on histopathology and biochemical parameters of kidney in adult male mice. *Sci J Kurdistan Univ Med Sci*. 2015;20(4):83-90.
- Roushandeh AM, Ansari S, Brouki Milan P, Mohammadnejad D, Delazar A, Mortazavi M. Effects of Polygonum avicular Extract on Histological Changes of Mouse Seminiferous Tubules after Electromagnetic Field Exposure. *Pharm Sci*. 2014;19(4):139-44.
- Mohammadi S, Moghimian M, Torabzadeh H, Langari M, Nazeri R, Karimi Z, et al. Effects of sodium selenite on formaldehyde induced renal toxicity in mice. *Pharm Sci*. 2016;22(4):227-33. doi:10.15171/ps.2016.36
- Aebi HU. In: Bergmeyer HU editor. *Methods in Enzymatic Analysis*. 2nd ed. New York: Academic

- Press; 1983. p. 276-86.
19. Wang X, Sheng N, Cui R, Zhang H, Wang J, Dai J. Gestational and lactational exposure to di-isobutyl phthalate via diet in maternal mice decreases testosterone levels in male offspring. *Chemosphere*. 2017;172:260-7. doi:10.1016/j.chemosphere.2017.01.011
 20. Kalantar M, Shirali S, Hasanvand A, Valizadeh M, Tavakoli R, Asadi M, et al. Ameliorative effects of hydroalcoholic extract of *lavandula officinalis* L. on methotrexate-induced oxidative stress in rats. *Pharm Sci*. 2017;23(1):18-26. doi:10.15171/ps.2017.04
 21. Zohni K, Zhang X, Tan SL, Chan P, Nagano MC. The efficiency of male fertility restoration is dependent on the recovery kinetics of spermatogonial stem cells after cytotoxic treatment with busulfan in mice. *Hum Reprod* 2012;27:44e53
 22. Bordbar H, Esmailpour T, Dehghani F, Panjehshahin MR. Stereological study of the effect of ginger's alcoholic extract on the testis in busulphan-induced infertility in rats. *Iran J Reprod Med*. 2013;11(6):467-72.
 23. Jung SW, Kim HJ, Lee BH, Choi SH, Kim HS, Choi YK, et al. Effects of Korean red ginseng extract on busulfan-induced dysfunction of the male reproductive system. *J Ginseng Res*. 2015;39(3):243-9. doi:10.1016/j.jgr.2015.01.002
 24. Abd-Elrazek AM, Ahmed-Farid OAH. Protective effect of L-carnitine and L-arginine against busulfan-induced oligospermia in adult rat. *Andrologia*. 2017;50(1):e12806. doi:10.1111/and.12806
 25. Dehghani F, Hassanpour A, Poost-Pasand A, Noorafshan A, Karbalay-Doust S. Protective effects of L-carnitine and homogenized testis tissue on the testis and sperm parameters of busulfan-induced infertile male rats. *Iran J Reprod Med*. 2013;11(9):693-704.
 26. Souli A, Sebai H, Chehimi L, Rtibi K, Tounsi H, Boubaker S, et al. Hepatoprotective effect of carob against acute ethanol-induced oxidative stress in rat. *Toxicol Ind Health*. 2013;31(9):802-10. doi:10.1177/0748233713475506
 27. Mohammadi S, Khakbaz M, Shoraka M, Vakil S, Moghimian M, Mohammadzadeh F, et al. Effects of different doses of manganese on lead poisoning in the kidney of adult male mice. *Koomesh*. 2016;18(1):203-10.
 28. Mohammadi S, Safari F, Seyed Z, Seyed Hosseini E, Karimi F, Mohammadi M, et al. Effect of different doses of N-acetyl cysteine on biochemical and histopathological parameters in kidney of formalin-treated. *J Kansai Med Univ*. 2016;23(5):607-17