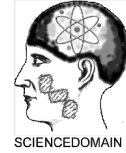



**Ophthalmology Research: An International Journal**  
2(6): 275-280, 2014, Article no. OR.2014.6.003

SCIENCEDOMAIN international  
[www.sciencedomain.org](http://www.sciencedomain.org)



## **Osteogenic Osteosarcoma of the Orbit: A Case Report**

**Rahmi Duman<sup>1\*</sup>, Sibel Özdoğan<sup>1</sup>, Mehmet Balcı<sup>1</sup>, Ercan Kahraman<sup>2</sup>  
and Olcay Kandemir<sup>2</sup>**

<sup>1</sup>Department of Ophthalmology, Ankara Oncology Hospital, Ankara, Turkey.

<sup>2</sup>Department of Pathology, Ankara Oncology Hospital, Ankara, Turkey.

### **Authors' contributions**

*The manuscript has no prior presentation or part of the work in a conference/seminar. We declare that there is no financial support or relationships that may pose conflict of interest.*

*Finally, there is no conflict of interest in connection with this submitted article, and the manuscript has been read and approved by all the authors.*

**Case Study**

**Received 24<sup>th</sup> March 2014**  
**Accepted 14<sup>th</sup> May 2014**  
**Published 27<sup>th</sup> May 2014**

### **ABSTRACT**

Osteogenic osteosarcoma of the orbit is a rare and aggressive type of osteosarcoma. Head and neck osteosarcomas occur most commonly in the third and fourth decades and have equal sex predisposition. A 56-year-old male patient was admitted to our clinic with proptosis on the left side and ptosis that had been present for five months. Ophthalmic examination revealed normal eye movements and vision. There was no pain and no paresthesia or any other significant complaint or clinical finding. Magnetic resonance imaging studies showed a hyperintense, destructive extraconal mass lesion adjacent to the lateral wall invading retrobulbar fat tissue of the left orbit. The patient underwent a lateral orbitotomy. Histopathological examination revealed osteogenic osteosarcoma of the orbit. Herein, we report a case with osteogenic osteosarcoma arising from the orbit is presented. The differential diagnoses of this tumor and the surgical results of radical resection are also presented.

**Keywords:** Osteosarcoma; orbit; tumor; exenteration.

\*Corresponding author: E-mail: [drrahmi42@yahoo.com](mailto:drrahmi42@yahoo.com);

## 1. INTRODUCTION

Osteogenic osteosarcoma of the orbit is an extremely rare osteogenic tumor [1-4]. Osteogenic osteosarcoma is a malignant bony tumor mesenchymal cell origin and because of the relative rarity of this condition, there are no clearly defined evidence-based treatment guidelines for the management of these tumors [3]. In this report, we describe the clinical, radiologic, and pathologic records of a rare case of primary osteogenic osteosarcoma of the orbit in a middle-aged man, with no previous history of trauma or surgery.

## 2. CASE REPORT

A 56-year-old male patient was admitted to our clinic with proptosis on the left side and ptosis that had been present for five months. At presentation at our clinic, his visual acuity was 10/10 in the right eye and 10/10 in the left eye. Ophthalmic examination revealed normal eye movements and vision. There was no pain and no paresthesia or any other significant complaint or clinical finding. Physical examination was otherwise unremarkable.

Consent was obtained from the patient. Magnetic resonance imaging studies showed a hyperintense, destructive extraconal mass lesion adjacent to the lateral wall invading retrobulbar fat tissue of the left orbita. The mass was lying extraconally and measuring 4x3x3cm.

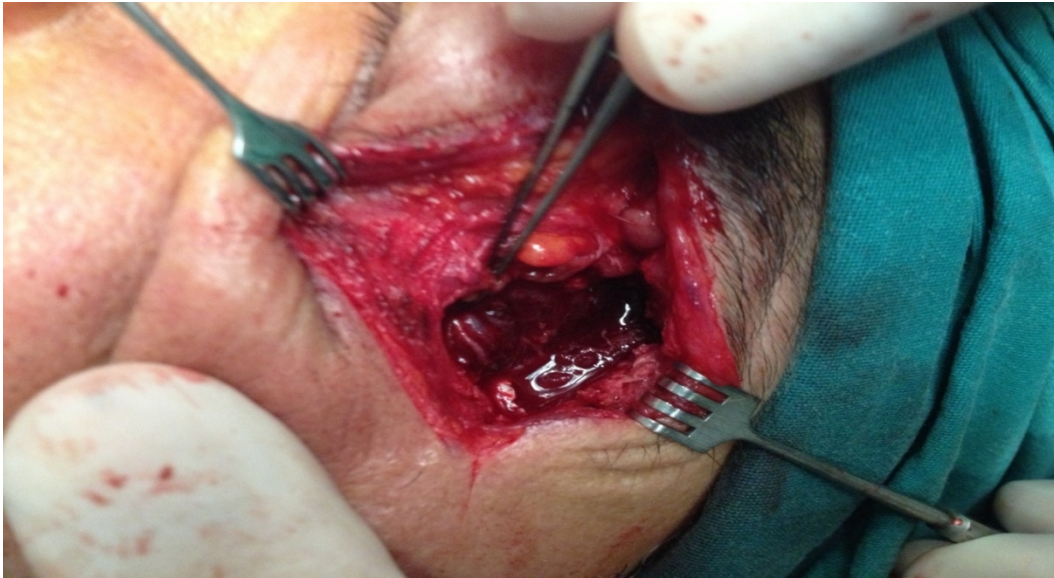The patient underwent a lateral orbitotomy. Exposure of the mass was achieved through a lateral orbitotomy. The zygomatic arch was also removed to obtain more exposure of the tumor. Intraoperatively, the tumor was found attached to the lateral wall of the orbit. The tumor appeared lobulated with a smooth capsule (Figs. 1-2).

Macroscopically, the tumor had a well-circumscribed cut surface, was grayish white, and had a solid nodular pattern. Histopathologic examination demonstrated extremely cellular and contained irregular cells accompanied by high mitotic activity and mineralized regions containing osteoid and the tumor cells had large hyperchromatic nuclei (Fig. 3). Tumor invasion into the adjacent tissue was observed. With regard to these histopathological findings, the diagnosis of osteosarcoma was established.

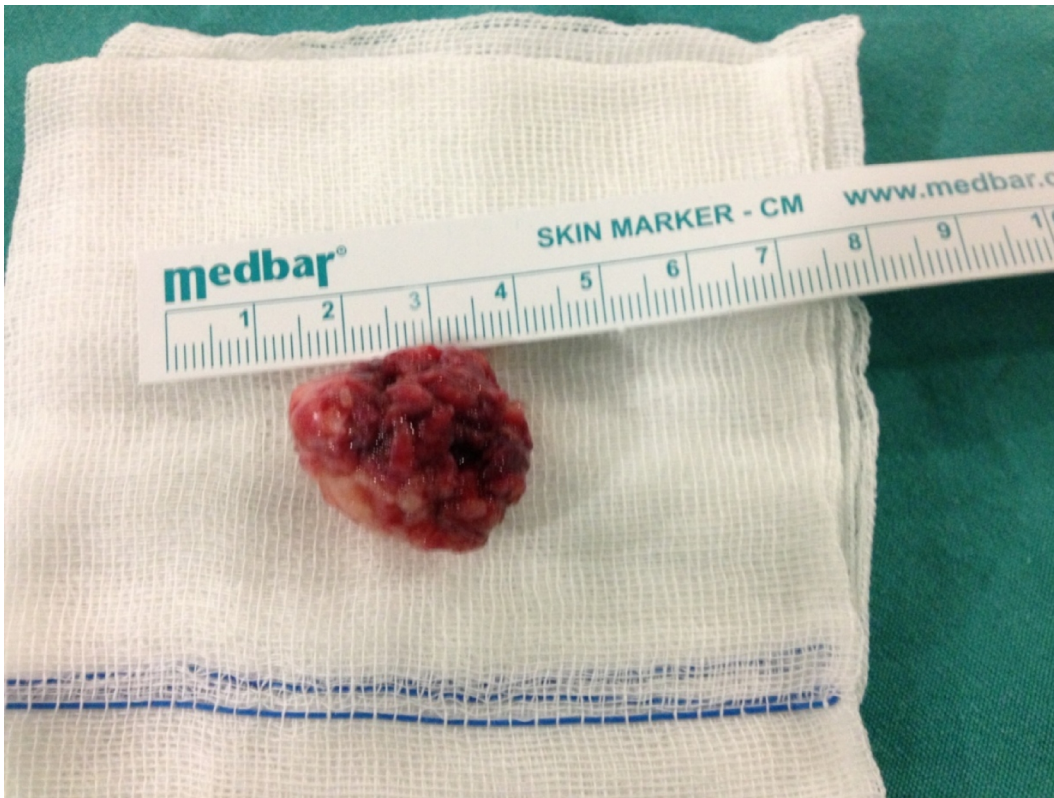Due to the invasive nature of the mass, the patient was referred to another center for chemotherapy, radiotherapy or exenteration without any further intervention. He underwent further excision of this mass. No metastasis was found during a radionuclide bone scan, chest, abdominal, and pelvis CT scans. No tumor recurrence or distant metastasis occurred during one year of follow-up.

## 3. DISCUSSION

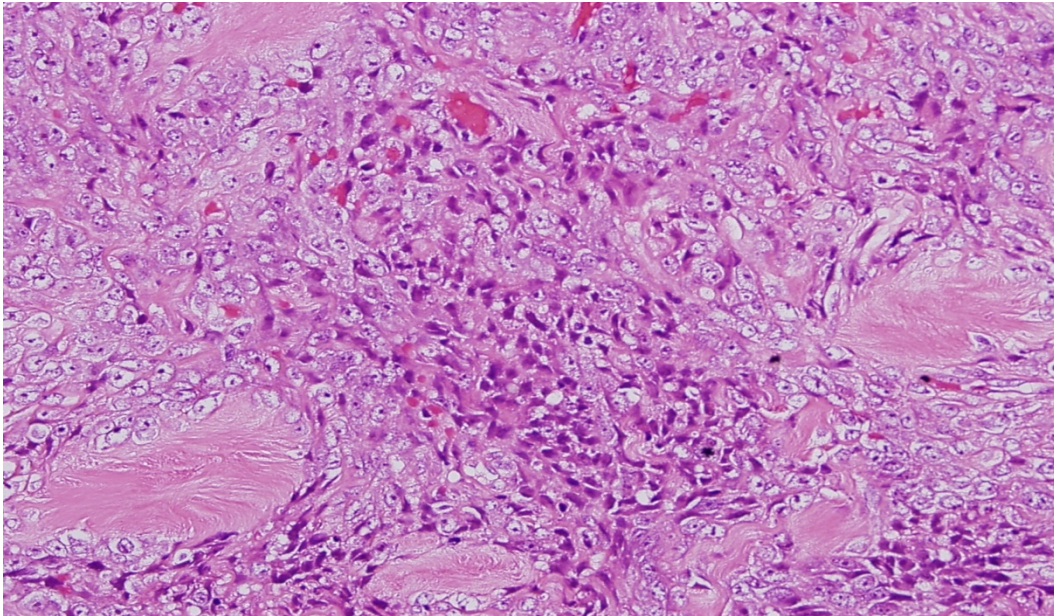
Osteogenic osteosarcomas of the head and neck origin are rare and aggressive malignancies [3-6]. Approximately 6% to 13% these tumors occur in the head and neck, and less than 2% occur in the cranium [2,4]. Predisposing conditions are Paget's disease of the bone, exposure to radiation, fibrous dysplasia, multiple osteochondromatosis, chronic osteomyelitis, myositis ossificans, and trauma [7,8]. There is no presenting predisposing factor in the story of the patient.



**Fig. 1. Gross appearance of the mass, The tumor appeared lobulated with a smooth capsule**



**Fig. 2. Gross appearance of the tumor**



**Fig. 3. Hematoxylin-eosin stain, original magnification x400, Osteogenic osteosarcom with extremely cellular and contained irregular cells accompanied by high mitotic activity and mineralized regions containing osteoid**

In the previous studies some histopathological subtypes were defined as chondroblastic, osteoblastic, fibroblastic and telangiectatic osteosarcoma. Chondroblastic and osteoblastic osteosarcoma were the most common subtypes [3,9].

Histologic diagnosis of parosteal osteosarcoma is often difficult, with the differential diagnosis including diverse conditions such as myositis ossificans and metaplastic bone formation in carcinoma, melanoma, synovial sarcoma and epithelioid sarcoma [10-13].

In our patient, the malignant cells and the absence of 'zonation' excluded a benign reactive condition such as myositis ossificans. Immunostains with melanocyte and epithelial markers were negative (S100, HMB-45, MELAN-A, EMA, LMWCK, HMWCK, Kromogranin respectively), thus excluding melanoma and carcinoma. In contrast, osteogenic sarcoma is characterized by a highly cellular pleomorphic anaplastic stroma, which forms amorphous islands of osteoid in addition to cartilage and fibrous tissue [14-16].

Although the optimal management of patients with osteosarcoma of the head and neck is still unclear, adequate surgical resection is the mainstay treatment [4,14-17] stated that the prognosis in osteosarcoma of the skull is poor and identified late diagnosis, early intracranial extension, and limited surgical excision as responsible factors. Osteogenic osteosarcomas occasionally invade the surrounding tissue, as in our case.

Surgeons might be reluctant to perform wide resections because of the complex anatomy of the fronto-orbital region and the very high rate of recurrence. When non-negative surgical margins are obtained, re-resection or adjuvant radiotherapy should be added as additional treatment. Smeele et al. [18] concluded that chemotherapy improves survival and advocated the use of similar chemotherapy protocols as used for osteosarcoma of the long bones.

#### **4. CONCLUSION**

Optimal management of patients with osteosarcoma of the head and neck is still unclear because of the relative rarity of this condition. There are no clearly defined evidence-based treatment guidelines for the management of these tumors. Adequate surgical resection is the most important step in treatment. Recurrence would be lower or the tumor-free period would be longer if negative margins could be obtained.

#### **CONSENT**

All authors declare that written informed consent was obtained from the patient for publication of this case report and accompanying images.

#### **ETHICAL APPROVAL**

Not applicable.

#### **COMPETING INTERESTS**

Authors have declared that no competing interests exist.

#### **REFERENCES**

1. Mark RJ, Sercarz JA, Tran L, et al. Osteogenic sarcoma of the head and neck: The UCLA experience. *Arch Otolaryngol Head Neck Surg.* 1991;117:761–66.
2. Ha PK, Eisele DW, Frassica FJ, et al. Osteosarcoma of the head and neck: A review of the Johns Hopkins experience. *Laryngoscope.* 1999;109:964–69.
3. Laskar S, Basu A, Muckaden MA, et al. Lessons learned from a single-institution experience of 50 patients. *Lessons Learned From A Single-Institution Head Neck.* 2008;30:1020-26.
4. Sundaresan N, Huvos AG, Rosen G, et al. Combined-modality treatment of osteogenic sarcoma of the skull. *J Neurosurg.* 1985;63:562–67.
5. Kassir RR, Rassekh CH, Kinsella JB, et al. Osteosarcoma of the head and neck: meta-analysis of nonrandomized studies. *Laryngoscope.* 1997;107:56–61.
6. Patel SG, Meyers P, Huvos AG, et al. Improved outcomes in patients with osteogenic sarcoma of the head and neck. *Cancer.* 2002;95:1495–1503.
7. Oda D, Bavisotto LM, Schmidt RA, et al. Head and neck osteosarcoma at the University of Washington. *Head Neck.* 1997;19:513–23.
8. Fan JC, Lamont DL, Greenbaum AR, Ng SG. Primary Orbital Extraskelatal Osteosarcoma. *Orbit.* 2011;30:297-9.
9. Bertoni F, Dallera P, Bacchini P, Marchetti C, Campobassi A. The Instituto Rizzoli-Beretta experience with osteosarcoma of the jaw. *Cancer.* 1991;68:1555–63.
10. Geschickter CF, Copeland MM. Parosteal osteoma of bone: a new entity. *Ann Surg.* 1951;133:790–807.
11. Campanacci M, Picci P, Gherlinzoni F, et al. Parosteal osteosarcoma. *J Bone Joint Surg Br.* 1984;66:313–21.
12. Okada K, Frassica FJ, Sim FH, et al. Parosteal osteosarcoma. A clinicopathological study. *J Bone Joint Surg Am.* 1994;76:366–78.
13. Sheth DS, Yasko AW, Raymond AK, et al. Conventional and dedifferentiated parosteal osteosarcoma. Diagnosis, treatment, and outcome. *Cancer.* 1996;78:2136–45.

14. Dhir SP, Munjal VP, Jain IS, et al. Osteosarcoma of the orbit. J Paediatr Ophthalmol Strabismus. 1980;17:312–4.
15. Rootman J, Chan KW. Osteogenic sarcoma. In Diseases of the Orbit: A Multidisciplinary Approach' Eds Rootman JB. Lipincott, Philadelphia. 1988;379–82.
16. Trevisani MG, Fry CL, Hesse RJ, Willis GW. A rare case of orbital osteogenic sarcoma. Arch Ophthalmol. 1996;114:494–5.
17. Morita R, Shimada K, Kawakami S. Low-grade central osteosarcoma of the orbit. J Craniofac Surg. 2012;23(3):178-80
18. Smeele LE, Kostense PJ, van der Waal I, Snow GB. Effect of chemotherapy on survival of craniofacial osteosarcoma: A systematic review of 201 patients. J Clin Oncol. 1997;15:363–67.

---

© 2014 Duman et al.; This is an Open Access article distributed under the terms of the Creative Commons Attribution License (<http://creativecommons.org/licenses/by/3.0>), which permits unrestricted use, distribution, and reproduction in any medium, provided the original work is properly cited.

*Peer-review history:*

*The peer review history for this paper can be accessed here:*  
<http://www.sciencedomain.org/review-history.php?iid=523&id=23&aid=4715>