



# Rehabilitation of Partially Edentulous Posterior Mandible with Bilateral Impacted Second Premolars Using TTPHIL- ALL TILT® Implant Technique: A 3-years Follow-up Case Report

Venkat Ratna Nag <sup>a,b,c++#†\*</sup>, Sarika V Puppala <sup>b‡</sup>,  
Bhavna V Lokwani <sup>b^</sup> and Manikandhan R <sup>a##</sup>

<sup>a</sup> Meenakshi Ammal Dental College, Chennai, India.

<sup>b</sup> Institute for Dental Implantology, Hyderabad, India.

<sup>c</sup> Department of Prosthodontics and Implantology, Panineeya Dental College, Hyderabad, India.

## **Authors' contributions**

*This work was carried out in collaboration among all authors. Author VRN designed the study, performed the statistical analysis, wrote the protocol, and wrote the first draft of the manuscript. Author SVP managed the analyses of the study. Author BVL managed the literature searches, and edited the manuscript draft. Author MR guided and reviewed the method and manuscript draft. All authors read and approved the final manuscript.*

## **Article Information**

### **Open Peer Review History:**

This journal follows the Advanced Open Peer Review policy. Identity of the Reviewers, Editor(s) and additional Reviewers, peer review comments, different versions of the manuscript, comments of the editors, etc are available here: <https://www.sdiarticle5.com/review-history/116690>

**Case Report**

**Received: 25/02/2024**

**Accepted: 30/04/2024**

**Published: 06/05/2024**

<sup>++</sup> PhD Scholar;

<sup>#</sup> Professor;

<sup>†</sup> Director;

<sup>‡</sup> Clinical Director;

<sup>^</sup> Associate Prosthodontist;

<sup>##</sup> Head of Department;

\*Corresponding author: Email: [tdspublication@gmail.com](mailto:tdspublication@gmail.com);

## ABSTRACT

Loss of teeth in the posterior mandible leads to progressive alveolar bone resorption, superficial location of the inferior alveolar nerve (IAN), thereby diminishing the amount of hard and soft tissue available for implant placement. This biological process is compounded by the presence of impacted teeth. The presence of impacted mandibular premolars, though asymptomatic, might be discovered when a patient presents for replacement of missing teeth or a cystic lesion in an adjacent tooth. Placement of dental implants in such cases may require multiple surgeries, including bone augmentations or vestibuloplasty or nerve lateralization surgeries. These extensive surgical procedures are seldom used in clinical practice due to their complexity and potential damage to IAN. This article demonstrates TTPHIL-ALL-TILT® protocol for placement of tilted implants utilizing available bone, lingual and buccal cortical plate engagement, bypassing IAN and the impacted premolar, in the posterior partially edentulous mandible in an anxious patient.

*Keywords: Bicuspid; dental implants; immediate dental implant loading; implant-supported dental prosthesis; dental implantation; mandibular nerve.*

## 1. INTRODUCTION

The need for prosthetic rehabilitation of a posterior atrophic edentulous mandible is a common clinical problem [1]. It can be rehabilitated with implants but, adequate quantity and quality of bone are required to ensure the correct position of implants and a good esthetic outcome. Inadequate height of residual alveolar bone makes it impossible to place implants of adequate length as there is an increased risk of inferior alveolar nerve (IAN) damage. This damage can cause neurosensory impairment, ranging from mild paresthesia to complete anaesthesia and/or hyperesthesia, which affects oral functions such as drinking and speech, or skin preparation such as make-up application and shaving [2].

Possible solutions for the rehabilitation of atrophic posterior mandible, include vertical bone augmentations, using short or ultrashort implants [3] or tilted implants and transposition or lateralisation of IAN in combination with dental implant placement [4]. Bone augmentation procedures such as guided bone regeneration (GBR) procedures, alveolar distraction osteogenesis, onlay and inlay bone grafting can aid in restoring alveolar bone volume but the rate of failures is found well over 20% [5]. These procedures are generally demanding for both clinicians and patients and are often associated with increased surgical risks and financial cost as well. Moreover, they involve high waiting time and morbidity making it a non-ideal solution for medically compromised patients [6]. Short implants are used when there is a minimum of 6 mm residual bone height and width. However, short implants (<6 mm) have presented a 29%

higher risk of failure compared to longer implants [7]. Although transposition or lateralisation of the mandibular nerve can be accompanied by implant placement, it is seldom used due to its complexity and potential IAN damage [2]. The use of tilted implants placed in the premolar and molar areas, bypassing the inferior alveolar nerve, could be a minimally invasive treatment option without the use of expensive bone grafts or morbid surgical procedures [4].

Mandibular second premolars, after third permanent molars and maxillary permanent canines, are the third most frequently impacted teeth. The prevalence of impacted premolars has been found to vary according to age. The overall prevalence in adults has been reported to be 0.5%; the range being 0.2-0.3% for mandibular premolars [8]. Its incidence though not common, can present as a surgical hindrance in implant rehabilitations. Asymptomatic impacted teeth do not warrant surgical removal [9]. However, when patients seek rehabilitation of the impacted site, its presence must be dealt with. Treatment requires either orthodontic movement to the ridge or its surgical removal both of which are usually invasive, lengthy and expensive. In the event of invasive surgical removal, sometimes, reconstruction of the bony site may be needed prior to implant placement [10].

A clinical situation that presents bilateral impacted second premolars in the posterior mandible demands the best of both surgical and prosthetic implant protocols to serve the purpose of implant rehabilitation with immediate function. This case report describes a minimally invasive approach for rehabilitating a patient with an unusually positioned impacted 2nd premolar

(crown lying lingual to the root apices of 1st molar tooth), with tilted implant placement bypassing the IAN and the tooth on both sides, presuming it will contribute towards the available literature regarding rehabilitation of such complex cases. The lingual orientation of the crown and root of this impacted 2nd premolar makes this case report rare.

## 2. PRESENTATION OF CASE

A 49 year old male patient visited the clinic (The Dental Specialists, Hyderabad, India) with the chief complaint of pain in the lower left back tooth and dislodged lower right bridge since 1 month. Patient was highly anxious and had controlled hypertension and hypothyroidism. Past dental history revealed that the lower bridge was done about 12 years back. On examination, it was

found that there was a splinted mandibular bridge extending from tooth #36 to #46 (FDI tooth numbering system). The bridge was ill-fitting with food lodgment in the posterior regions and mobile at #46 region. The region of #34 presented with tenderness on percussion. (Fig. 1) The remaining maxillary teeth were sound. The patient was subjected to panoramic radiography (OPG) and cone-beam computed tomography (CBCT) that demonstrated periapical infection with respect to #34, periodontitis in #46, missing teeth #31,32,42,42,35,45; secondary caries in #36 and bilateral impacted second premolars. (Fig. 2) The radiographs also revealed resorption of the alveolar bone, a residual bone height at #45 region being 10mm; #47 being 6mm; #36 being 9mm with minimal residual bone between impacted premolar and adjacent teeth.

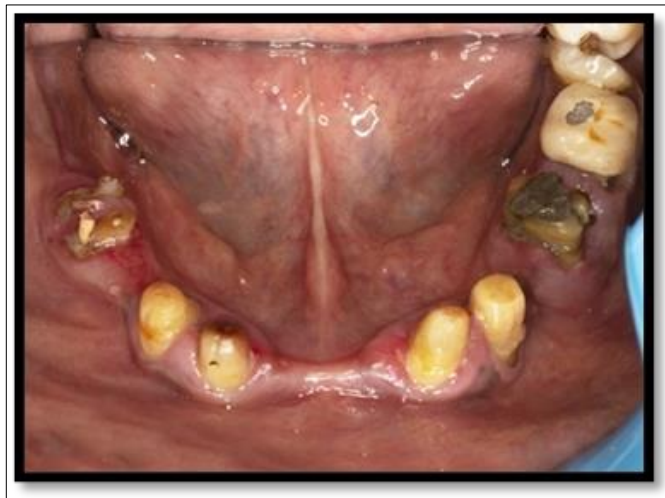

Fig. 1. Pre-operative intraoral occlusal view of mandibular teeth

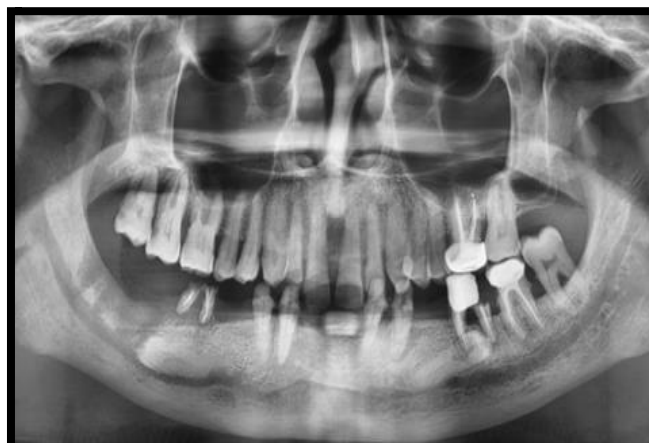

Fig. 2. Pre-operative radiograph

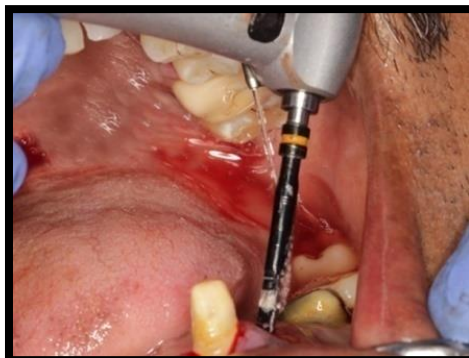
Considering the medical history and apprehension of the patient, it was necessary to provide minimally invasive fixed implant treatment and immediate function without any impaction surgeries and augmentations to avoid any delay in the completion of treatment. Further, the patient was reluctant to come for multiple visits. Therefore, disimpaction of the second premolars and subsequent bone augmentations were ruled out. It was decided that implants using TTPHIL: ALL TILT® technique could be recommended wherein tilted implants would bypass the IAN and engage available cortical bone of mandible to attain objectives of primary stability and osseofixation, subsequently delivering immediate function. After obtaining signed consent for the proposed treatment plan, oral prophylaxis was done. Implant placement at #34, #36, #45, #47 were planned. Intentional root canal treatments were done in #33, #43, #44 on the same day.

In the next appointment, one hour prior to surgery, Amoxicillin 1g was given orally and was followed up with 500mg for 3times/ daily for the next 3 days. #34,#36, #46 were extracted and immediate tilted implants were placed subcrestally following TTPHIL: ALL TILT®

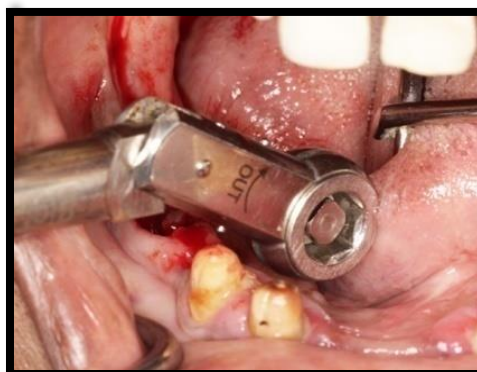protocol. 3.75 x16 mm implant (Bioline I, BiolineDental GmbH&Co.KG) was placed at #34 region. The implant osteotomies were performed with a single drill using a freehand technique (Fig. 3).

In the region of #36, 3.75 mm x13 mm implant was placed in a tilted manner. Another implant (3.75x13mm) was placed at #45 in a similar manner. #47 region received tilted short implant (6x6mm) as the vertical height above the inferior alveolar canal was only 4mm that limits the use of a long tilted implant. (Figs. 3A, 3B) All implants were placed tilted to bypass the inferior alveolar nerve in a flapless manner. Because of cortical engagement, high torques were achieved with the implants. (Fig. 4) CBCT was taken to confirm the same (Fig. 5).

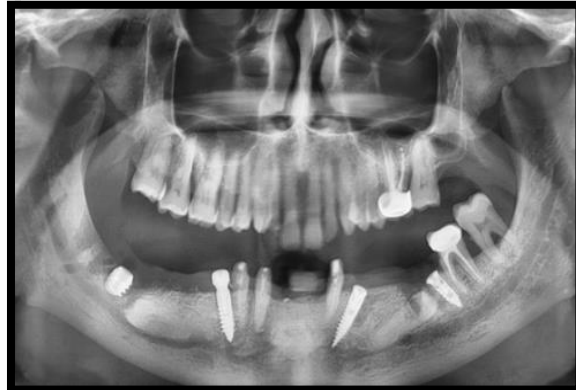Platform-switched micro-grooved multiunit abutments were placed in the same surgery and corresponding open tray transfer copings were used for impressions. Elastomeric impressions were made for provisional restoration. The bite records were made using aluwax and temporary fixed partial implant supported dentures were fabricated for the purpose of immediate function.



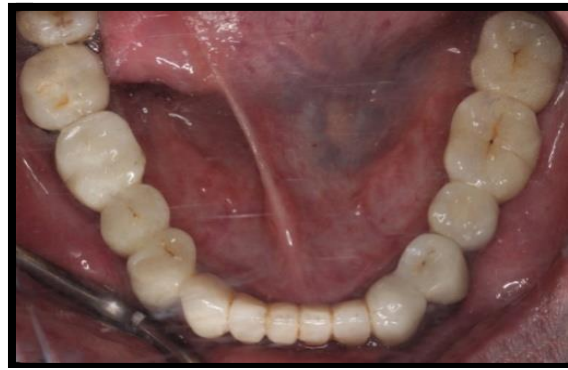**Fig. 3. Osteotomy site performed using single drill**



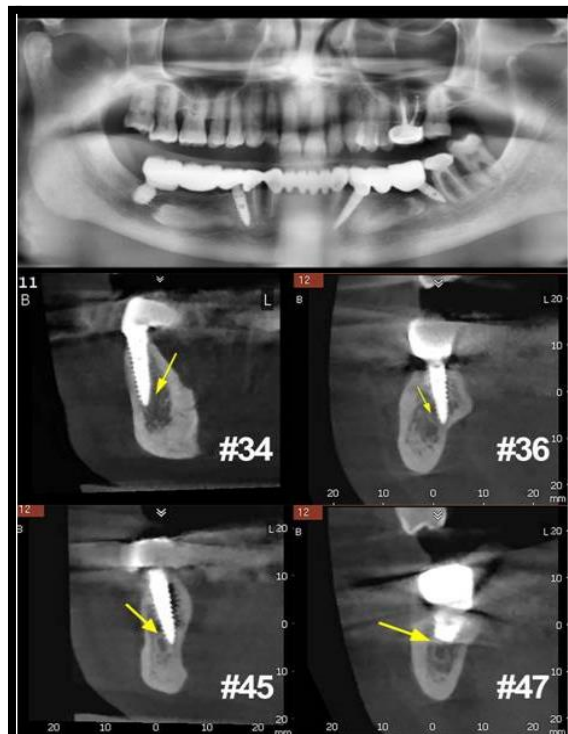
**Fig. 4. High torques achieved with immediate implant placement**



**Fig. 5. Radiographic view of the implants placed**



**Fig. 6. Screw retained metal ceramic definitive prosthesis**



**Fig. 7. Radiographic view of 3 year follow up of prosthesis showing stable crestal bone and no signs of inflammation**

On the next day, temporary fixed partial implant supported dentures were checked for fit and occlusal corrections done. The bridges were luted using intermediate restorative cement (ZnOE). Check up for the patient was also done for any loss of sensation in the lower lip and chin. No neuro-sensory changes were noted. The patient was reviewed after 1 week, then every month for three consecutive months and it was uneventful. The patient reported after 1 year for fabrication of cement-retained permanent metal-ceramic bridges. The prosthetic procedure remained the same as for provisional restorations. A Metal ceramic bridge was fabricated and the fit was checked (Fig. 6).

Any premature contacts during lateral and protrusive movement were avoided and the bridges were cemented. A one year follow up was done for 3 years, the implants and prosthesis were evaluated and a CBCT taken each time. (Fig. 7) The nerve integrity of IAN and the stability of the bone tissue surrounding the dental implants were also assessed using reverse torque test.

### 3. DISCUSSION

In the rehabilitation of posterior mandible, the position of inferior alveolar canal with adjacent impacted mandibular premolars can be a challenge to implant placement. The literature is lacking on previously reported cases of rehabilitation in the posterior mandible with bilateral impacted premolars without disimpaction surgery. This clinical case describes the TTPHIL: ALL TILT® technique of oral rehabilitation of posterior partially edentulous mandible in a patient with multiple comorbidities employing a bridge supported by four implants with splinted prosthesis, which bypass the inferior alveolar nerve. The choice of the present treatment was based on the necessity to reduce patient discomfort and visits, using a minimally invasive treatment path with a high level of predictability in a highly anxious patient.

The TTPHIL: ALL TILT® technique stands for Tall Tilted implants placed in a Pin Hole manner for Immediate Loading. The tilted implants bypass the inferior alveolar nerve and are anchored in the cortical bone of the mandible, achieving cortical anchorage for subsequent primary stability for immediate function [11]. Furthermore, the tilted implants suppressed the need for surgical disimpactions and consequent bone grafting procedures, leading to higher

patient acceptance. Another clinical advantage of tilting implants is that it aids in the usage of taller implants, increasing the implant-bone contact area. The position of implants was intended to restore immediate function in a highly anxious patient with the aid of CBCT. Subcrestal placement helped in minimizing implant thread exposure by compensating for subsequent bone loss [12]. Flapless surgery reduced postoperative morbidity and preserves soft and hard tissue integrity. Single osteotomy drill method reduced the effect of drilling temperatures on the bone, thereby aiding to achieve improved vascularization that favours bone regeneration [13]. Single-stage surgery with abutments placed in the same appointment minimizes surgical visits, increasing patient acceptance as well as maintaining mucosal integrity without disrupting the mucosal barrier. In this case, single-stage surgery reducing the surgical appointments favored acceptance in an anxious patient. Platform switching rendered a positive effect on crestal bone levels by internal positioning of implant-abutment junction that moves the bacterial inflammatory infiltrate away from the adjacent crestal bone [14]. Encompassing all these concepts, TTPHIL: ALL TILT® technique harnesses each of its advantages to the present clinical situation.

The use of conventional implants as a treatment alternative would have mandated the need for multiple surgical appointments for impactions and waiting time for healing which the presented anxious patient had not preferred. Any nerve lateralization surgery was not accepted due to its invasiveness. Further, short implants were not used for all teeth as an alternative, due to their limited predictability in the long run [7]. Nevertheless, one short implant was used due to the extremely limited residual bone above the IAN preventing placement of long tilted implant. In the posterior mandible where vertical ridge augmentation tends to be a challenging procedure with moderate predictability, the use of short implants seems to offer a minimally invasive alternative but precludes the bone-implant contact as can be achieved with longer tilted implants.

### 4. CONCLUSION

The current protocol of posterior partial mandibular rehabilitation with four implants inserted, two anterior and two posterior to the impacted second premolars, could be a viable option for restoring functions and improving



quality of life especially in an anxious patient. However, an experienced surgical and restorative team, a CBCT investigation and precise planning, the existing residual bone volume, the degree of mouth opening are important factors to be considered. Studies using a larger sample size and longer follow-up should be performed to draw definitive conclusions. No complications occurred during the 3-year follow-up, demonstrating this technique as a successful surgical and restorative option.

## CONSENT

As per international standards or university standards, patient(s) written consent has been collected and preserved by the author(s).

## ETHICAL APPROVAL

It is not applicable.

## COMPETING INTERESTS

Authors have declared that no competing interests exist.

## REFERENCES

1. Felice P, Pellegrino G, Checchi L, Pistilli, Esposito M. Vertical augmentation with interpositional blocks of anorganic bovine bone vs 7mm long implants in posterior mandibles: 1-year results of a randomised clinical trial. *Clin Oral Implants Res.* 2010;21:1394-1403. Available: <https://doi.org/10.1111/j.1600-0501.2010.01966.x>.
2. Nishimaki F, Kurita H, Tozawa S, Teramoto Y, Nishizawa R. Subjective and qualitative assessment of neural disturbance after inferior alveolar nerve transposition for dental implant placement. *Int J Implant Dent.* 2016;2:14. Available: <https://doi.org/10.1186/s40729-016-0047-1>
3. Krekmanov L. Placement of posterior mandibular and maxillary implants in patients with severe bone deficiency: a clinical report of procedure. *Int J Oral Maxillofac Implants.* 2000;15(5):722–30.
4. Pistilli R, Zucchelli G, Barausse C, Bonifazi L, Karaban M, Gasparro R et al. Minimally invasive fixed rehabilitation of an extremely atrophic posterior mandible using 4-mm ultrashort implants: A case report with a 7year follow-up. *Int.J.Periodontics Restor.Dent.* 2020;40(6):e235-e240. DOI:10.11607/prd.4157
5. Pistilli R, Barausse C, Checchi L, Felice P. Rehabilitation of the atrophic posterior mandible with short (4-mm) implants: A case report. *Int.J.PeriodonticsRestor.Dent.* 2014;34(5):713-718. DOI:10.11607/prd.1733
6. Filipov L, Chirila L, Cristache MC. Rehabilitation of extremely atrophic edentulous mandible in elderly patients with associated comorbidities: A case report and proof of concept. *Head & Face Medicine.* 2021;17:22. DOI:10.1186/s13005-021-00274-2
7. Papaspyridakos P, De Souza A, Vazouras K, Gholami H, Pagni S, Weber H-P. Survival rates of short dental implants ( $\leq 6$  mm) compared with implants longer than 6 mm in posterior jaw areas: A meta-analysis. *Clinical Oral Implants Research.* 2018;29:8–20. Available: <https://doi.org/10.1111/clr.13289>
8. Chu FCS, Li TKL, Lui VKB, Newsome PRH, Chow RLK, Cheung LK. Prevalence of impacted teeth and associated pathologies-A radiographic study of Hong Kong Chinese population. *Hong Kong Med J.* 2003;9:158-163.
9. Ferguson JW, Pitt SK. Management of unerupted maxillary canines where no orthodontic treatment is planned; A survey of UK consultant opinion. *J Orthod.* 2004;31:28-33. Available: <https://doi.org/10.1179/146531204225011337>
10. Becker A, Chaushu S. Success rate and duration of orthodontic treatment for adult patients with palatally impacted maxillary canines. *Am J Orthod Dentofacial Orthop.* 2003;124:509-514. DOI:10.1016/s0889-5406(03)00578-x.
11. Romanos GE, Cionei G, Jucan A, Malmstrom H, Gupta B. *In vitro* assessment of primary stability of Straumann® implant designs. *Clin Implant Dent Relat Res* 2014;16:89-95. DOI:10.1111/j.1708-8208.2012.00464.x.
12. Koh RU, Oh T-J, Rudek I, Neiva GF, Misch CE, Rothman ED, Wang H-L. Hard and soft tissue changes after crestal and subcrestal immediate implant placement. *Journal of Periodontology.* 2011;82(8): 1112–1120. DOI:10.1902/jop.2011.100541

13. R Bettach, S Taschieri, G Boukhris, M Del Fabbro. "Implant survival after preparation of the implant site using a single bur: A case series." *Clinical Implant Dentistry and Related Research*. 2015;17(1)13–21.
14. Aimetti M, Ferrarotti F, Mariani GM, Ghelardoni C, Romano F. Soft tissue and crestal bone changes around implants with platform-switched abutments placed nonsubmerged at subcrestal position: a 2-year clinical and radiographic evaluation. *Int J Oral Maxillofac Implants*. 2015, Nov-Dec;30(6):1369-77. DOI:10.11607/jomi.4017

---

© Copyright (2024): Author(s). The licensee is the journal publisher. This is an Open Access article distributed under the terms of the Creative Commons Attribution License (<http://creativecommons.org/licenses/by/4.0>), which permits unrestricted use, distribution, and reproduction in any medium, provided the original work is properly cited.

*Peer-review history:*

*The peer review history for this paper can be accessed here:*  
<https://www.sdiarticle5.com/review-history/116690>