



## **A Systematic Review: Prevalence of C Shaped Configuration in Upper-maxillary and Lower-mandibular First Premolar**

**Nadia Buraik<sup>a#</sup>, Abdulaziz Abdullah Alnafjan<sup>b#</sup>, Fahad Khalid Almana<sup>c#</sup>,  
Amani Essam Najjar<sup>d#</sup>, Abdulelah Mesfer Alrubayqi<sup>e#</sup>, Roqiah Zaki Alkhamis<sup>f#</sup>,  
Amirah Abdulaziz Alotaibi<sup>f#</sup>, Mohammed Thafar Aldosari<sup>g#</sup>,  
Dalal Jumah Alturaif<sup>h#</sup>, Laila Mohammad Alanazi<sup>i</sup>, Ahmed M. Elmarakby<sup>j</sup>  
and Fatima Sultana<sup>i\*</sup>**

<sup>a</sup> Afif General Hospital, Ministry of Health, Saudi Arabia.

<sup>b</sup> Dawadmi General Hospital, Ministry of Health, Saudi Arabia.

<sup>c</sup> King Saud University, Saudi Arabia.

<sup>d</sup> Al-farabi Dental College, Saudi Arabia.

<sup>e</sup> Taymaa General Hospital, MOH, Saudi Arabia.

<sup>f</sup> Private Clinic, Saudi Arabia.

<sup>g</sup> Al-artawiah General Hospital, Ministry of Health, Saudi Arabia.

<sup>h</sup> Obeid Specialized Hospital, Saudi Arabia.

<sup>i</sup> Department of Dentistry, Research Center Riyadh Saudi Arabia.

<sup>j</sup> Restorative Dental Sciences, Saudi Arabia.

### **Authors' contributions**

*This work was carried out in collaboration among all authors. All authors read and approved the final manuscript.*

### **Article Information**

DOI: 10.9734/JPRI/2021/v33i60B34771

### **Open Peer Review History:**

This journal follows the Advanced Open Peer Review policy. Identity of the Reviewers, Editor(s) and additional Reviewers, peer review comments, different versions of the manuscript, comments of the editors, etc are available here: <https://www.sdiarticle5.com/review-history/81973>

**Systematic Review Article**

**Received 22 October 2021**

**Accepted 20 December 2021**

**Published 23 December 2021**

### **ABSTRACT**

In most cases, the C-shaped pattern is found in mandibular second molars. Additionally, C-shaped canals can also occur in mandibular premolars, maxillary molars, and mandibular third molars. It poses challenges like debridement, obturation, and possibly the outcome of root canal treatment. The purpose of this study is to make a systematic review of studies related to the prevalence and morphology of C shaped canals in premolar teeth. Using pre-designed forms, data were extracted

<sup>#</sup> General Dentist;

<sup>\*</sup>Corresponding author: E-mail: fatimaismail22@gmail.com;

from online databases such as Medline and PubMed Central. We extracted citations and characteristics of studies, such as names of authors, date of publication, country, title, definition of C shaped canal configuration, and classification of C shaped canal configuration in upper and lower first premolars. Even though they are rare, mandibular premolars are also known to have C-shaped canal systems. Approximately 10-18% of mandibular first premolars have C-shaped canals, according to studies. Treatment is more challenging for patients with C-shaped canals. The frequency of C-shaped configurations in premolar teeth is likely to be affected by regional characteristics and gender of the population. Having these factors in mind before surgery allows dentists to better plan, coordinate, and perform complex morphologies.

**Keywords:** *Cone Beam Computed Topography (CBCT); C shaped canal; first pre molars; mandibular first premolar; maxillary first pre molar.*

## 1. INTRODUCTION

An infected tooth can be saved or repaired using root canal therapy. It is an alternative to extraction of the damaged tooth. A thorough understanding of the tooth and its morphology is essential to a successful root canal treatment. A tooth with a C-shaped canal morphology has been observed. "Gutter shaped root canal" was named by Nakayama in 1941 when he discovered the first C-shaped canal. C-shaped root canals were first identified by Cooke and Cox in 1979.

The endodontist must be knowledgeable of the root canal morphology and its variations to treat patients consistently. A patient's root canal anatomy varies greatly from one person to another. Many factors can contribute to these variations, including gender and race. The mandibular/maxillary first premolar canals exhibit complex configurations. Earlier studies have documented a high incidence of Type I canal patterns. It is possible that the various root canal morphologies of these teeth contribute to their high failure rate with regard to endodontic treatment.

Studies have been conducted on the root canal morphology of mandibular/maxillary first premolars in diverse populations, such as Chinese, Asian, European, Mexican, American and African American. During a review of the literature, we found that there has been little research on root canal morphology among Saudi populations. The two most common ways to study root canal anatomy are radiography and clearing technique, followed by observations under a microscope, 3D reconstructions, and macroscopic sectioning.

Radiography, which utilizes a two-dimensional image of a three-dimensional object, has the

problem of superimposition. After removing the extracted teeth from the mouth, the root canals are stained with ink to clear the teeth. By demineralizing and soaking in methyl salicylate, the teeth become clear. Following the removal of the teeth, the root and root canal systems are examined and recorded. Preparing teeth for study can affect the pulp space and surrounding structures, while other methods cause problems.

The roots and canals of the first premolar in the mandibular/maxillary region can sometimes degenerate. Upon inspection, it was discovered that the canals of this tooth are shaped like a C. In contrast to its maxillary counterpart, the mandibular first premolar usually has a more oval external outline than its maxillary counterpart. When a straight line is followed to access the tooth, the lingual inclination of the crown allows buccal extension to approach the tip of the buccal cusp. Despite an extended lingual cusp, the cusp inclination is poorly developed. There is a complex anatomy of the root canal typically found near the apical half of the tooth root and it may need to be modified to reach it. It is usually centered mesiodistally, between the cusp tips.

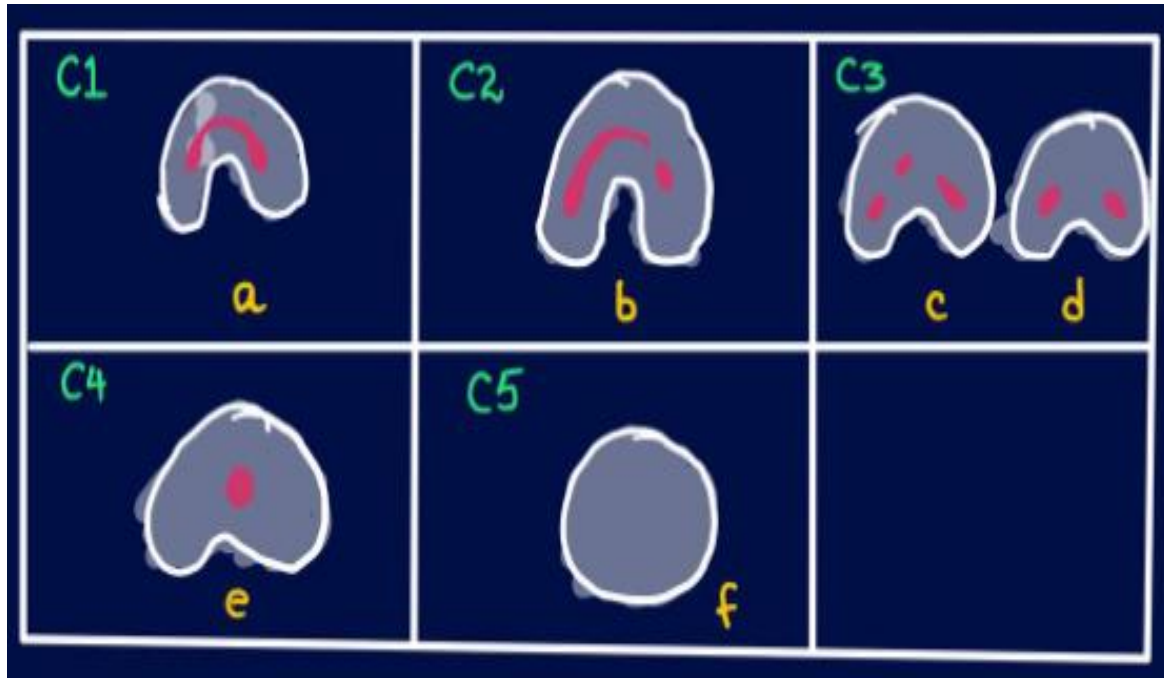
Root canal clearance can be done with stereomicroscopes. There are cases of asymmetrical teeth as well as those with bilateral symmetry. Recently, the cone beam computed tomography (CBCT) along with spiral computed tomography (SCT) has been used to identify the C-shaped canal in dentistry. Using the ultrasonic equipment, the canals are cleaned and irrigated effectively. After the cleaning and irrigation of the root canals, the filling of canal is done to avoid the infection with bacteria. A high degree of micro-leakage can be noticed if sealing agents are not used.

When the canal morphology resembles the shape of a C, the cross section of the root and

canal is shaped in this way. In the anatomical sense, it consists of fins or isthmuses that connect the root canals, and the orifice may have an arc of 180° or more, resulting in variations in cross-sectional shape and three-dimensionality. It can be challenging for a dentist to effectively

debride, disinfect, and fill canals due to this morphological complexity [1].

According to Melton, the C shaped canals can be classified into 5 groups, described below:



**Fig. 1. Classification of C shaped canal by Melton**

Chart 1: Categories of canal configuration

- |   |
|---|
| <p>a) Category I (C1): The shape was an interrupted 'C' with no separation or division.</p> <p>b) Category II (C2): The canal shape resembled a semicolon resulting from a discontinuation of the 'C' outline, but either angle or should be no less than 60°.</p> <p>c) Category III (C3): Two or three separate canals and both angles, and were less than 60°.</p> <p>d) Category IV (C4): Only one round or oval canal in that cross-section.</p> <p>e) Category V (C5): No canal lumen could be observed (which is usually seen near the apex only).</p> |
|---|

Studies assessing mandibular premolars have not always reported root and root canal configuration.

## 2. AIM AND OBJECTIVES

The main aim of this study is to systematically review the studies that are related to the prevalence of C shaped first premolars.

### Specific objectives:

- 1.Reviewing about the history of C shaped first premolars.
- 2.Understanding the morphology of C shaped canals occurring in the first premolars.
- 3.Identifying the advantages and disadvantages of occurrence of the C shaped canal configuration.
- 4.Carrying the online literature review using the different databases to determine the prevalence of morphology of C shaped first premolars.

### 3. METHODOLOGY

Our search process incorporated specific terms and filters according to PubMed Central and Medline databases in order to find prevalence studies on radiographs of root/canal anatomy.

#### 3.1 Search Terms Used

The Boolean operators were used to determine and evaluate the prevalence and Morphology of the C shaped canal configuration in first premolars like: (C-shaped root canal OR C-shaped pulp canal) AND (First Premolars)/ (C-shaped root canal OR C-shaped pulp canal) AND (Bicuspid)/ (C-shaped root canal OR C-shaped pulp canal) AND (First Posterior tooth).

Following the application of the additional filters "last 25 years" [PDat] AND Humans [Mesh] AND English [Lang], the number of 93 articles was reduced to 12. We independently screened titles and abstracts of the articles in this section, and any disagreements were resolved by discussion. Inclusion/exclusion criteria included:

#### 3.2 Inclusion and Exclusion Criteria of Study

The study aims to review and evaluate the previous research on the C shaped canal configuration using this method. Article submissions need to be screened after they have been submitted for study eligibility.

##### Inclusion Criteria:

- ✓ all case studies or articles that were published in the English language
- ✓ studies related to C-shaped canals in the first premolars
- ✓ articles or cases with C-shaped canal configurations
- ✓ Studies that treated both genders (males and females)
- ✓ Studies that considered endodontic therapies of c shaped canal.

##### Exclusion Criteria:

- ✓ Studies that treated non-human subjects

- ✓ Studies with the same ethical approval number or duplicates
- ✓ Studies with different conventional endodontic treatments
- ✓ studies without C-shaped canals

#### 3.3 Data Extraction and Management

The data must be extracted from Medline and PubMed Central via an electronic form designed by the principal investigator. According to the inclusion and exclusion criteria of this study, the systematic was carried out. An extensive literature search was performed on citations, references of the included studies and related systematic reviews, as well as an extensive manual search of major journals in endodontics and dentistry. Search terms and controlled vocabulary were developed by two independent reviewers using PubMed as a starting point and adapted to other electronic databases using free-text terms.

### 4. RESULTS

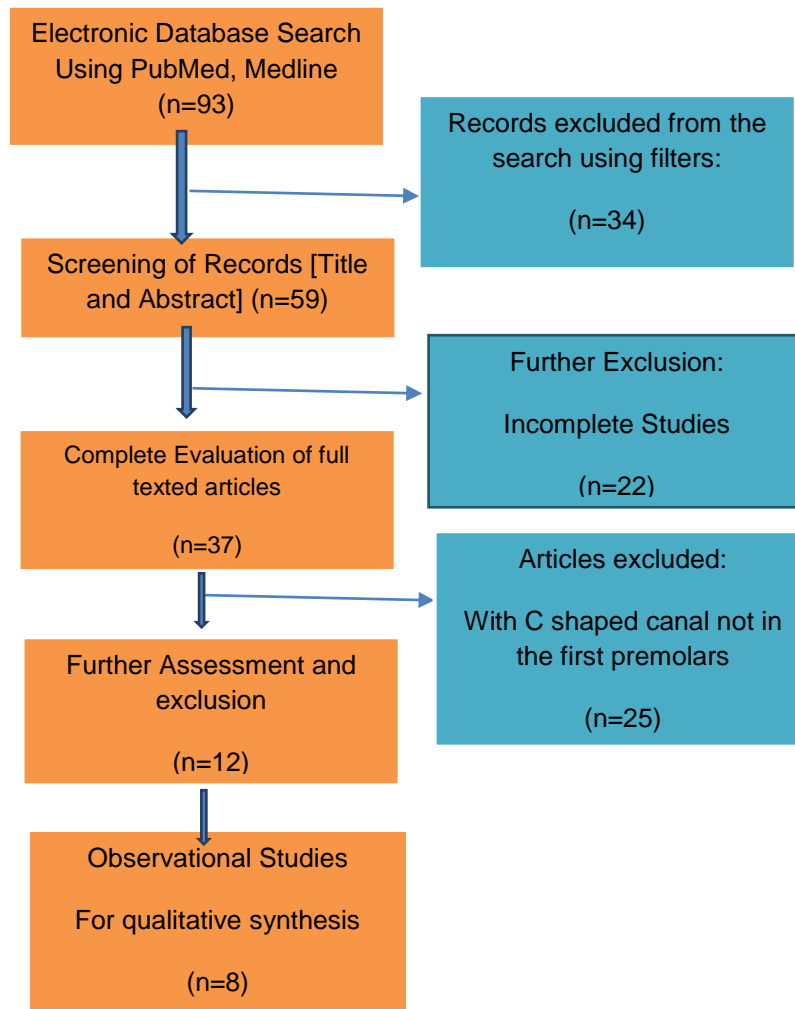
- **Formulation of Research Question:** Carrying the online systematic review using the different databases to determine the prevalence of morphology of C shaped first premolars.
- **Identification of Key Concepts:** Studying and understanding the concept of C shaped canals found in the first premolars.
- **Development of Search Terms:** The search terms were developed using the free-text terms by adding variations.
- **Development of Search Terms:** Using controlled vocabulary terms by identification in thesaurus.
- **Use of Boolean Operators:** (C-shaped root canal OR C-shaped pulp canal) AND (First Premolars)/ (C-shaped root canal OR C-shaped pulp canal) AND (Bicuspid)/ (C-shaped root canal OR C-shaped pulp canal) AND (First Posterior tooth).
- **Search Filters:** Use of various filters like only Human studies, only studies in English language were applied.
- **Optimization of the systematic review**
- **Evaluation of the results after screening.**
- **Identification of Errors.**

Chart 2. Analysis of observational studies

SNO	Author's Name	Year of Study	Country of Research	Title of Study	Study Publisher	Number of Investigations don	Radiographic techniques used	Prevalence of C shaped root canals reported	Investigations reported
1	Saeed Rahimi [2]	2007	Iran	Root Canal Configuration of Mandibular First and Second Premolars in an Iranian Population	Journal of Dental Research	163 extracted mandibular first	Radiography and clearing techniques	The prevalence of C-shaped canals was 2.4% in mandibular first molars	The incidence of three canals in the mandibular first premolars was 1.2%
2	N. Velmurugan [3]	2008	India	Root canal morphology of mandibular first premolars in an Indian population: a laboratory study	International Endodontic Journal	100 extracted adult mandibular first premolar teeth	Decalcification and clearing techniques	The mandibular first	Type I canal patterns were the most frequently occurring in mandibular first premolars amongst the Indian population.
3	Bing Fan [4]	2008	China	Root Canal Systems in Mandibular First Premolars with C-shaped Root Configurations. Part I: Microcomputed Tomography Mapping of the Radicular Groove and Associated Root Canal Cross-sections	Journal of Endodontics	358 mandibular first pre molar	Microcomputed Tomography Mapping	Of the total 358 mandibular first pre molar, 86 of the teeth showed C shaped canals.	The radicular grooves may present relevant morphologic variations in the root canal system when the C-shaped root is present
4	B. Fan [5]	2012	China	Three-dimensional morphological analysis of C-shaped canals in mandibular first	International Endodontic Journal	146 mandibular first premolars	Three-dimensional morphological analysis	Of 146 mandibular first premolars 97 had C-shaped canals, the predominant	In teeth from a Chinese population, mandibular first premolars with

SNO	Author's Name	Year of Study	Country of Research	Title of Study	Study Publisher	Number of Investigations don	Radiographic techniques used	Prevalence of C shaped root canals reported	Investigations reported
				premolars in a Chinese population				anatomical canal	radicular grooves had a high incidence of C-shaped canal systems with anatomical variations along the root.
5	Jojo kottoor [6]	2013	India	Root Anatomy and Root Canal Configuration of Human Permanent Mandibular Premolars: A Systematic Review	Anatomy Research International	12,752 first premolars	Microcomputed tomography	The most common anatomic variation was C-shaped canals in mandibular first premolars with highest incidence in Mongoloid populations (up to 24%)	A systematic review of mandibular premolars Based on ethnicity and geographic clusters offered enhanced analysis of the prevalence of number of roots and canals, their canal Configuration, and other related anatomy.
6	Yong-chun Gu [7]	2013	China	A Micro-Computed Tomographic Analysis of Wall Thickness of C-shaped Canals in Mandibular First Premolars	Journal of Endodontics	148 mandibular first molars	Micro-computed tomographic imaging	The incidence of c shaped canals is 67.3% for the mesial walls and 69.2% for the distal walls.	The mesial walls of C-shaped canals in mandibular first premolars are the thinnest zones.
7	Avi Shemesh [8]	2020	Israel	Radicular Grooves and Complex Root Morphologies of Mandibular	Journal of Endodontics	1835 mandibular first premolars	Cone-beam computed tomography scans	The overall prevalence of complex root morphology	Complex root canal morphology frequently occurs in mandibular first

SNO	Author's Name	Year of Study	Country of Research	Title of Study	Study Publisher	Number of Investigations don	Radiographic techniques used	Prevalence of C shaped root canals reported	Investigations reported
				Premolars Among Israeli Population				(types II–VIII) in mandibular first and second premolars was 21% and 2.8%, respectively.	premolars in the population of Israel.
8	Mashyakhy M H [9]	2020	Saudi Arabia	C-shaped canal configuration in mandibular premolars and molars: Prevalence, correlation, and differences: An In Vivo study using cone-beam computed tomography	Nigerian Journal of Clinical Practice	1433 mandibular premolars CBCT scans from the Saudi population were evaluated	Cone-beam computed tomography	The prevalence of C-shaped canals in the first premolars was 1.5%	Although the prevalence of C-shaped canals is significantly higher in mandibular second molars, they are also found in mandibular premolars but in small percentages. No significant differences were found between both genders and both sides.



**Fig. 2. Flow chart of screening and identification of the articles related to the C shaped Canal**

The total articles screened were about 93. The filters were added like Human Studies, English language studies and studies that included adults. About 34 articles were excluded from the research after applying the filters. Remaining 59 articles were screened for the reading the title and abstract. All the incomplete studies that were around 22 were excluded. Only 37 articles were left that were complete. Upon further reviewing, all the studies without the C shaped canal configuration in the first premolars were removed. Further assessment and exclusion of the articles related to the C shaped canal configuration in the first pre molar was done with 12 articles. The observational studies were carried out in about 8 articles and the qualitative synthesis were obtained.

## 5. DISCUSSION

One of the most common causes of endodontic therapy failure is failure to identify and obturate

the root canal system appropriately. Hermetic seals are crucial to the long-term success of root canal treatment. In a clinical setting, it is not always possible to locate all canals, and sometimes they are not adequately sealed. The success of endodontic treatment depends not only on the clinician's technical skills, but also on the body's ability to heal, resistance to infection, the state of the periapical tissues and the surrounding periodontium, as well as any systemic diseases. Additionally, other factors such as age, sex, race, and tooth distribution might also contribute to the failure of endodontic treatment.

Dental procedures require a thorough understanding of the external and internal anatomy of human teeth. Because of the variations in their root canal morphology, human mandibular first premolars are notoriously difficult to endodontize. Tooth variants of this type have a



wide range of variations, coupled with a relatively high incidence of abnormalities [7]. Furthermore, differences in root canal shape have been linked to nonsurgical root canal treatment failures and high incidence of endodontic flare-ups. A radial groove on the external root surface is often associated with an ovoid-shaped cross section or other complex shape. In mandibular first premolars, Tome's root is an external anatomy variation characterized by the development of radicular grooves at different levels associated with the transformation from one root to multiple roots.

Anatomically, a C-shaped canal system is most commonly found in mandibular second molars. Even though they are rare, C-shaped canal systems are also found in mandibular premolars. According to studies, C-shaped canals are found in mandibular first premolars at a range of 10-18%. Treatment is more difficult for patients with C-shaped canals.

Several root canals are connected by a web or fin in a C-shaped canal [9]. It is impossible to instrument C-shaped canals with almost any type of NiTi rotary file due to their irregular configuration. In order to ensure sterility prior to obturation, a combination of NiTi instruments, ultrasonic irrigations, and intracanal medication are necessary.

Multiple studies have shown that the prevalence of C-shaped root canal systems in mandibular second molars ranges from 2.7 to 44.5%, depending on ethnicity and study design. In Korea and China, C-shaped canals are most prevalent in East Asian regions. The Burmese population accounted for the highest prevalence (22.4%), followed by Indians (12.3%) and Thais (10%). The prevalence rates for Russian and Portuguese populations have been reported as being respectively 14 and 8.5%. Radiographic interpretation in Europe, however, showed a lower prevalence (5%), possibly due to limitations associated with the technique studied [10].

Because of the existence of apical deltas, intercanal communications, and lateral canals, treating mandibular first premolars might be difficult. These must all be thoroughly diagnosed before treatment can begin. Biomechanical preparation as well as a sealer with perfect flowability must be applied during treatment. Nearly half of the teeth were found to have apical foramen laterally. The working length may seem

short on radiographs in circumstances where the foramen opens laterally [11].

An electronic apex locator is used in this case to measure the working length repeatedly, which is determined by the radiograph. In vitro, micro-CT is an effective non-destructive tool to evaluate root canal morphology. It is simple to view cross sections of sample teeth with 3D analysis software and correlate external anatomy with internal canal morphology. There is obvious diversity in root architecture and root canal shape for the treatment of mandibular first premolar root canals, which necessitates thorough assessment.

Post-endodontic restoration of teeth with C-shaped canal configurations may also be compromised due to the relatively small amount of dentin between the root surface and the internal canal system. The tooth structure around a post should be at least 1 mm strong to prevent root fracture. There is an increased risk of strip perforation with prefabricated or cast posts [12]. In addition, a prefabricated post would not fit a C-shaped canal (circular or conical in cross section). A deep pulp chamber floor can provide ample retention for the undercuts.

In such cases, a chamber-retained, bonded amalgam or composite restoration is the right option. The use of cone-beam CT and operating microscopes can help doctors better understand anatomical variations. The continuous anticurvature filing around the circumference of the C-shaped root canal enhances ultrasonic activation of sodium hypochlorite tissue removal. Using lateral and cold vertical condensation as obturation techniques improves the density of filling as well as the adaptation to the changes in temperature [13-30].

A C shaped canal can be found in a tooth on one side over 70% of the time. Mandibular premolars were historically considered the most difficult teeth to endodontically treat. When endodontic surgery is indicated, the extraction, retrofilling, and intentional re-implantation of a molar with a C-shaped root canal anatomy are strong considerations. First premolar canals can be shaped in many ways. As soon as these structures are discovered, they can be cleaned, shaped, and obturated. If C-shaped canals are suspected in a patient's clinical and radiographic records, this must be considered.

## 6. CONCLUSION

We found that regional characteristics and gender of the population affected the prevalence of C-shaped premolar configurations, whereas age was not a factor. Prior to surgery, if dentists were familiar with these factors, they could plan, coordinate, and perform complex morphologies more accurately. A cross-sectional study of root canal anatomy using CBCT is an important future research topic. By using study checklists, researchers can provide readers with a more reliable and reproducible method of studies, reducing the chances of bias. A detailed description of the patients' demographics should be provided.

## CONSENT

It is not applicable.

## ETHICAL APPROVAL

It is not applicable.

## COMPETING INTERESTS

Authors have declared that no competing interests exist.

## REFERENCES

1. Easley TO, Ren Z, Kim B, Karczmar GS, Barber RF, Pineda FD. Enhancement-constrained acceleration: A robust reconstruction framework in breast DCE-MRI. *PLoS One*. 2021;16(10):e0258621.
2. Rahimi S, Shahi S, Lotfi M, Zand V, Abdollahi M, Es'haghi R. Root canal configuration and the prevalence of C-shaped canals in mandibular second molars in an Iranian population. *Journal of Oral Science*. 2008;50:9–13.
3. Velmurugan N, Sandhya R. Root canal morphology of mandibular first premolars in an Indian population: A laboratory study *International Endodontic Journal*. 2009;42:54–8.
4. Fan B, Yang J, Gutmann JL, Fan M. Root canal systems in mandibular first premolars with C-shaped root configurations. Part I: Microcomputed tomography mapping of the radicular groove and associated root canal cross-sections. *Journal of Endodontics*. 2008;34:1337–41
5. Fan B, Ye W, Xie E, Wu H, Gutmann JL. Three-dimensional morphological analysis of C-shaped canals in mandibular first premolars in a Chinese population. *International Endodontic Journal*. 2012;45:1035–41.
6. Kottoor J, Velmurugan N, Ballal S, Roy A. Four-rooted maxillary first molar having C-shaped palatal root canal morphology evaluated using cone-beam computerized tomography: A case report. *Oral Surgery, Oral Medicine, Oral Pathology and Oral Radiology*. 2011;111:e41–5
7. Gu Y, Zhang Y, Liao Z, Fei X. A micro-computed tomographic analysis of wall thickness of c-shaped canals in mandibular first premolars. *Journal of Endodontics*. 2013;39(8):973–976.
8. Shemesh Avi, Lalum Ella, Ben Itzhak Joe, Levy Dan Henry, Lvovsky Alex, Levinson Oleg, Solomonov Michael. Radicular grooves and complex root morphologies of mandibular premolars among Israel population. *Journal of Endodontics*; 2020.
9. Mashyakhly MH, Chourasia HR, Jabali AH, Bajawi HA, Jamal H, Testarelli L, Gambarini G. C-shaped canal configuration in mandibular premolars and molars: Prevalence, correlation, and differences: An *In vivo* study using cone-beam computed tomography. *Nigerian Journal of Clinical Practice*. 2020;23:232-9.
10. Yu X, Guo B, Li KZ, Zhang R, Tian YY, Wang H, et al. Cone-beam computed tomography study of root and canal morphology of mandibular premolars in a western Chinese population. *BioMed Central (BMC) Imaging*. 2012;12:18.
11. Hakan Arslan, Huseyin Ertas, Elif Tarim Ertas, Fahrettin Kalabalik, Gokhan Saygili, Ismail Davut Capar. Evaluating root canal configuration of mandibular incisors with cone-beam computed tomography in a Turkish population. *Journal of Dental Sciences*. 2015;10(4):359-364. ISSN 1991-7902
12. Martins JN, Mata A, Marques D, Anderson C, Carames J. Prevalence and characteristics of the maxillary Cshaped molar. *Journal of Endodontics*. 2016a;42:383–9.
13. Pedemonte E, Cabrera C, Tores A, et al. Root and canal morphology of mandibular premolars using cone-beam computed tomography in a Chilean and Belgian subpopulation: a cross-sectional study. *Oral Radiology*. 2018;34:143–50.

14. Manning SA. Root canal anatomy of mandibular second molars. Part I: International Endodontic Journal. 1990;23:34-9.
15. Manning SA. Root canal anatomy of mandibular second molars. Part II: C-shaped canals. International Endodontic Journal 1990;23:40-5.
16. Cooke HG 3rd, Cox FL. C-shaped canal configurations in mandibular molars. J Am Dent Assoc. 1979;99:836-9.
17. Bolger WL, Schindler WG. A mandibular first molar with a C-shaped root configuration. Endodontic Journal. 1988;14:515-9.
18. Naseri M, Haghighi AK, Kharazifard MJ, Khavid A. Prevalence of C-shaped root canals in Iranian population: A systematic review. Journal of Dentistry of Tehran University. 2013;10(2):186-96. Epub 2013 Mar 31.
19. Alghamdi FT, Khalil WA. Root canal morphology and symmetry of mandibular second premolars using cone-beam computed tomography. Oral Radiology; 2021.
20. Ahmed HMA, Dummer PMH. A new system for classifying tooth, root and canal anomalies International Endodontic Journal. 2018;51(4):389-404.
21. Baisden MK, Kulild JC, Weller RN. Root canal configuration of the mandibular first premolar. Journal of Endodontics. 1992;18:505-8.
22. Sikri VK, Sikri P. Mandibular premolars: aberrations in pulp space morphology. Indian Journal of Dental Research. 1994;5:9-14.
23. Lu TY, Yang SF, Pai SF. Complicated root canal morphology of mandibular first premolar in a Chinese population using the cross section method. Journal of Endodontics. 2006;32:932-6.
24. Al-Fouzan KS. C-shaped root canals in mandibular second molars in a Saudi Arabian population. International Endodontic Journal. 2002;35(6):499-504.
25. Algarni YA, Almufarrij MJ, Almoshafi IA, Alhayaza HH, Alghamdi N, Baba SM. Morphological variations of mandibular first premolar on cone-beam computed tomography in a Saudi Arabian sub-population. Saudi Dental Journal. 2021;33(3):150-155.
26. Newton CW, McDonald S. A C-shaped canal configuration in a maxillary first molar. Journal of Endodontics. 1984;10(8):397-9.
27. Dou L, Li D, Xu T, Tang Y, Yang D. Root anatomy and canal morphology of mandibular first premolars in a Chinese population. Scientific Reports. 2017;7(1):750.
28. Fernandes M, de Ataíde I, Wagle R. C-shaped root canal configuration: A review of literature Journal of Conservative Dentistry 2014;17(4):312-9.
29. Kato A, Ziegler A, Higuchi N, Nakata K, Nakamura H, Ohno N. Aetiology, incidence and morphology of the C-shaped root canal system and its impact on clinical endodontics. International Endodontic Journal. 2014;47(11):1012-33.
30. Wang Y, Guo J, Yang HB, Han X, Yu Y. Incidence of C-shaped root canal systems in mandibular second molars in the native Chinese population by analysis of clinical methods. International Journal of Oral Science. 2012;4(3):161-5.

© 2021 Buraik et al.; This is an Open Access article distributed under the terms of the Creative Commons Attribution License (<http://creativecommons.org/licenses/by/4.0>), which permits unrestricted use, distribution, and reproduction in any medium, provided the original work is properly cited.

*Peer-review history:*

*The peer review history for this paper can be accessed here:*  
<https://www.sdiarticle5.com/review-history/81973>