



## **Development and Feasibility of a Very Low-cost, Home-made, Near Infrared Lymphatic Imaging Device**

**P. T. Luis López Montoya<sup>1</sup>, M. D. Luis Roberto García Valadez<sup>1,2</sup>,  
P. T. Yucari López<sup>1,2</sup>, P. T. Joceline Sandoval<sup>1</sup>, P. T. Angel López Montoya<sup>1\*</sup>,  
P. T. Itzel Alcaraz<sup>1</sup> and P. T. Claudia Paz<sup>1</sup>**

<sup>1</sup>*Fi Fisioterapia Integral S.C., Calle San Juan Bosco 1333, Col. Camino Real, Zapopan, Jalisco, México.*

<sup>2</sup>*Military Regional Hospital of Specialties of Guadalajara Jalisco, Av. del Ejército 100 Colonia Reformal, Zip 44890, Zapopan, Jalisco, Mexico.*

### **Authors' contributions**

*This work was carried out in collaboration among all authors. Author PTLLM developed the NIR imaging device, author MDLRGV designed the study. Author PTYL performed the statistical analysis, author PTJS wrote the protocol, author PTALM wrote the first draft of the manuscript. Authors PTIA and PTCP managed the analyses of the study. Author PTLLM managed the literature searches. All authors read and approved the final manuscript.*

### **Article Information**

DOI: 10.9734/JAMMR/2020/v32i2230706

#### Editor(s):

(1) Dr. Chan-Min Liu, Xuzhou Normal University, China.

#### Reviewers:

(1) Yip Foo Win, Universiti Tunku Abdul Rahman, Malaysia.

(2) Marvel L. Akinyemi, Covenant University, Nigeria.

Complete Peer review History: <http://www.sdiarticle4.com/review-history/62779>

**Original Research Article**

**Received 02 September 2020**

**Accepted 08 November 2020**

**Published 27 November 2020**

### **ABSTRACT**

**Introduction:** Near Infrared (NIR), lymphatic Imaging is an emergent imaging technique used to assess superficial lymphatic structures and its function. It uses a NIR light source and a special camera that detects the fluorescence of a non-radioactive dye called indocyanine green (ICG), which is injected subdermally and its way through lymphatic capillaries, making this device useful in the diagnosis and follow up of lymphatic diseases.

**Objective:** To show (NIR) step-by-step development of a feasible, user-friendly, and low-cost homemade Near Infrared (NIR) lymphatic imaging device.

**Methods:** Using worldwide available components such as a customized laser and a modified webcam, we assembled what is a functional plug and play NIR lymphatic imaging device

\*Corresponding author: E-mail: [lopzmontoy@figdl.com](mailto:lopzmontoy@figdl.com), [montoya\\_301192@hotmail.com](mailto:montoya_301192@hotmail.com);

and evaluated its function with a 25-year-old healthy woman.

**Conclusion:** It is feasible to build a functional, homemade, low-cost Near Infrared (NIR) lymphatic imaging device in a tenth of its value.

*Keywords: NIR-imaging; NIR-ICG imaging; NIR-lymphangiography; NIR lymphatic imaging; lymphatic imaging; lymphedema; lymphology; lymphatic system.*

## 1. INTRODUCTION

Near Infrared (NIR) lymphatic imaging is an emergent imaging technique that allows a safe evaluation and assessment of structure and function of the superficial lymphatic system [1]. Compared to lymphoscintigraphy and direct lymphangiography, (NIR) lymphatic imaging is a cheaper, ambulatory, reliable and highly sensitive technique for the diagnosis of lymph related drainage imaging, with three main advantages such as; it doesn't requires the use of radioactive drugs, or special installations nor high cost equipment [2].

This device employs a Near Infrared wavelength light to excite and reach a fluorescent response from a chemical dye called green indocyanine (ICG), which is injected in a subdermal manner and later absorbed through regional lymphatic capillaries [3]. This imaging technique is used in oncological and reconstructive surgery [4].

NIR Imaging has been recently used to enhance the diagnosis [5], surgical and non-surgical treatment and investigation of lymphedema and lymphatic system related pathology [6]; even though of its low cost and worldwide reproducibility, this device has still not been popularized, because of its high cost and limited access to branded devices. This may explain why in Latin-American medical literature, the use of NIR Imaging for the diagnosis of lymphedema is barely mentioned and there is not an established protocol for the practice [7]. We suspected that some possible factors related to the underuse of NIR Imaging in developing countries may be due to high cost of its equipment, and the availability of the equipment resulting in the limitation of this technology.

The purpose of this study is to show a feasible and low-cost homemade NIR lymphatic imaging device for diagnosing lymphatic disease.

### 1.1 Background

According to the Pubmed's MeSH database and the International Society of Lymphology

Consensus, lymphedema is defined as a "chronic-progressive lymphatic disease which produces edema, due to the obstruction of lymph vessels or caused by disorders of the lymph nodes", this lack of transport, produces chronic fibrosclerotic changes in tissues and a inflammatory response [8], its progression affects the quality of life [9] and the economy of patients [10].

Lymphedema may occur due to primary congenital malformations of lymphatic and venous system or secondary to different agents that damage lymphatic structures such as lymph nodes, vessels, capillaries, such as parasite infection (filarial), cancer related (lymph node removal, radiotherapy, regional neoplasm), direct trauma, chronic skin cellulite infections, obesity and chronic venous insufficiency. It is estimated that more than 250 million patients around the world have a lymphatic disease [6-10].

Actually the diagnosis of lymphedema and its assessment is made clinically, supported by anthropometric and colometric measurements .This allows a precise follow up of the evolution of the edema [11-13] but this measures does not evaluate the structural and functional state of the lymphatic system. This represents a limit in the assessment of patients evolution in an objective way; The use of image analysis studies such as lymphoscintigraphy and lymphatic magnetic resonance [14], are used for the diagnosis and staging of lymphatic related pathology [15]; since introduced in 2007 as a "novel real-time image system", (NIR) lymphatic imaging has been suggested as an economic, accessible and easy to use choice for assessing morphologic changes in lymphatic vessels and its function, showing itself since introduced, as a superior to evaluate superficial lymphatic structures, but still not a very widespread, diagnosing tool compared to other image techniques [16].

In addition to the economic, accessible and user-friendly advantages if NIR lymphatic imaging, this technique has shown its predictive potential in asymptomatic breast- cancer related patients risk

in developing lymphedema improving the prognosis of these patients through an early diagnosis [17-19].

As shown in a systematic review developed by Antonio J Forte et al. 2019, the use of lymphoscintigraphy in the evaluation of the therapy and its progress in breast cancer related diseases, its lymphatic impairment or treatment effectiveness pretends to be of common use between lymphologists worldwide [1-5].

Given the need of this image device, we decided to describe a step by step self- building, easy to assemble (NIR) lymphatic Imaging tutorial as a description of its social network video <https://www.youtube.com/watch?v=-Ooc2wujslI>.

## 2. METHODS

### 2.1 Step 1, the Bandpass Filter

This step was to get an optic bandpass filter which allows of 830 nm  $\pm$ 45 nm electromagnetic wavelength spectrum with a >95% of transmission. This is the fluorescent spectrum of ICG dye, and a selective blockage of the rest of the electromagnetic spectrum waves, we must use the Edmund Optics Inc's filter of 832NMx37NM model BP 93T 25D. (Fig. 1) for this purpose.



**Fig. 1. Edmund Optics Inc's bandpass filter 832NMx37NM BP 93T 25D model**

### 2.2 Step 2, the Image System

Then, the image system is set with the use of a plug and play commercial webcam, which in this case was accomplished by using an ANC-Aoni brand 8 megapixels device (Fig. 2).


The next step was to modify this image device by transforming it into an infrared friendly cam by removing the default infrared blocking filter installed into the bottom of the lenses' camera barrel and replacing it with a wavelength filter (Fig. 3).



**Fig. 2. ANC-Aoni brand 8**



**Fig. 3. Replacement of infrared filter bandpass filter instead**



**Fig. 4. Customized laser modules**

### 2.3 Step 3, the Light Source


Once the camera is set, a light source is needed. The beam of light source must be around 780-800 nm wave length spectrum, so we have chosen two different wave length laser modules, one of 785 nm and two laser modules of 790 nm, both of them of 10mW output power, and a working voltage of DC 3-5V and 150 mA resistance. Lasers used for this custom project were bought in Higgs Laser Store, found in Ali Express (Fig. 4).

### 2.4 Step 4, Gadget Assembly

Lasers were installed in a radial disposition at 12, 3, 6 and 9 clockwise, in a self-made plastic montage for our camera and laser set; lasers were then connected using a basic parallel electronic circuit to a non-branded old cellphone

AC-DC adapter that fits out to our desired output (DC 3-5 V and 150 m A) (Fig. 5).

Once the lasers were connected and installed, the camera was also installed into the montage and fitted it to a tripod (Fig. 6).



**Fig. 5. Self-made montage for lasers and the camera disposition**



**Fig. 6. Final device installed and ready to use**

### 3. RESULTS

Our Near Infrared (NIR) lymphatic imaging device was firstly used under informed consent document, in the Regional Military Hospital Approval in Guadalajara Mexico in healthy 25-

year-old women in the regular NIR lymphatic image protocol, by using a 0.5 ml of ICG dye solution (15 mg into 5 ml of physiologic solution) into each interdigital webspace of the hand and subdermal over the styloid process of radius and ulna in the forearm (Fig. 7).

Once the camera was connected to the computer and laser beam was turned on, the arm was scanned in search for lymphatic pathways using different angles and distances.

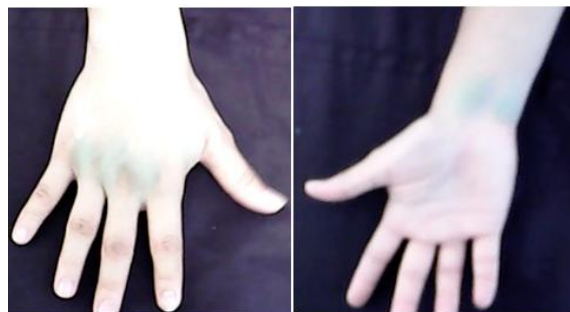
Fluorescence image of lymphatic pathways of forearm and arm was seen as in regular lymphatic vessel pattern.

Anatomical structures such as the palmar capillary lymphatic plexus (Fig. 8), its anterior ulnar and anterior radial lymphatic vessels pathways (Fig. 9). The cephalic lymphatic vessel pathway (Fig. 10) as well as the bicipital and basilic lymphatic vessels pathways (Fig. 11, Fig. 12), we identified and integrated as seen in Fig. 13.

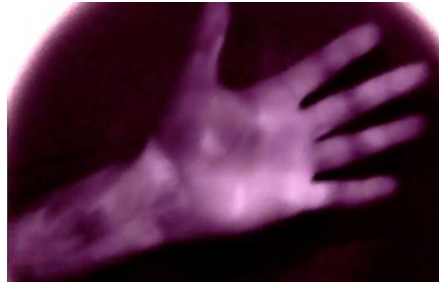
### 4. DISCUSSION

Even though the lymphatic vessel pathways were anatomically identified in our subject, the identification of lymphatic pathological patterns is needed in patients with lymphatic dysfunction, never the less the goal was accomplished, because it was possible to identify lymphatic vessels pathways and its drainage function, with a good image quality.

The price of the complete set was 375 USD which compared to the average ranged price of a Near Infrared (NIR) lymphatic imaging device which ranges over 10,000 USD and 20,000 USD; its considered that device is a tenth of its regular cost, making it accessible for researchers, developers and clinicians.



**Fig. 7. Intradermal sites of ICG dye administration**



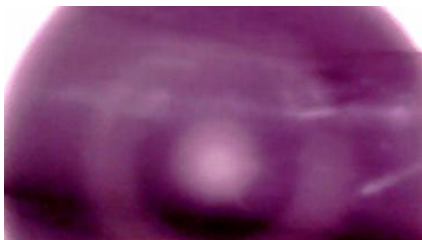**Fig. 8. Palmar lymphatic capillary plexus**



**Fig. 9. Up: anterior radial lymphatic pathway  
Down: anterior ulnar lymphatic pathway**



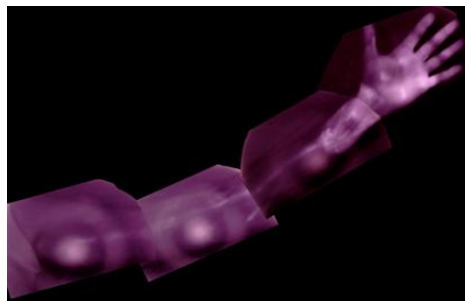
**Fig. 10. Up: Basilic lymphatic pathway  
Down: Bicipital lymphatic pathway**



**Fig. 11. Up: Cephalic lymphatic pathway  
Middle: Transition radial-basilic lymphatic pathway  
Down: Transition ulnar-bicipital lymphatic pathway**



**Fig. 12. Bicipital lymphatic pathway near axilla**



**Fig. 13. Integration of image sequence**

During the development of this device, some difficulties were identified due to the cameras auto-focus and auto-white-balance function, so its fair to suggest trying with different camera options prior to employ a definitive one, authors

design improvement will be shared in social media, by searching authors name; in the same way, identifying the exact distance related to the intensity and power of the beam were detected, for example: the closer to the limb the better

fluorescent spectrum was identified but this implied the loss of the shape of the limb as consequence of light refraction in the filter, in the other way, the far from the limb, the better shape was gotten; trying different laser intensities and power is suggested.

The development of this device offers a new and more economical alternative to regular commercial available devices at a very low cost with many of the same results for visualization of superficial lymphatics of the limbs [20]. And even with lower investment than other low-cost ICG lymphatic imaging devices documented in the literature [21]. It's fair to predict that the popularization of this low cost device will bring innovation in the use of NIR-ICG lymphatic imaging in different fields of research and clinical applications worldwide.

## 5. CONCLUSION

It is feasible to build a functional, home-made, very low-cost Near Infrared lymphatic imaging device in a tenth of its value.

## CONSENT

Authors declare that 'written informed consent was obtained from the participant for publication of this study and accompanying images.

## ETHICAL APPROVAL

Hereby, all authors declare that all experiments have been examined and approved by the appropriate ethics committee and have therefore been performed in accordance with the ethical standards laid down in the 1964 Declaration of Helsinki.

## COMPETING INTERESTS

Authors have declared that no competing interests exist.

## REFERENCES

- O'Donnell TF Jr, Rasmussen JC, Sevick-Muraca EM. New diagnostic modalities in the evaluation of lymphedema. *J Vasc Surg Venous Lymphat Disord.* 2017;5(2): 261-270.  
DOI: 10.1016/j.jvsv.2016.10.083  
Epub 2017 Jan 16. PMID: 28214496; PMCID: PMC5325714.
- Akita S, Mitsukawa N, Kazama T, Kuriyama M, Kubota Y, Omori N, Koizumi T, Kosaka K, Uno T, Satoh K. Comparison of lymphoscintigraphy and indocyanine green lymphography for the diagnosis of extremity lymphoedema. *J Plast Reconstr Aesthet Surg.* 2013;66(6):792-8; PMID: 23523168.  
DOI: 10.1016/j.bjps.2013.02.023
- Abbaci M, Conversano A, De Leeuw F, Laplace-Builhé C, Mazouni C. Near-infrared fluorescence imaging for the prevention and management of breast cancer-related lymphedema: A systematic review. *Eur J Surg Oncol.* 2019;45(10): 1778-1785.  
DOI: 10.1016/j.ejso.2019.06.009  
Epub 2019 Jun 8. PMID: 31221460.
- Struk S, Honart JF, Qassemyar Q, Leymarie N, Sarfati B, Alkhashnam H, Mazouni C, Rimareix F, Kolb F. Utilisation du vert d'indocyanine en chirurgie sénologique et reconstruction mammaire [Use of indocyanine green angiography in oncological and reconstructive breast surgery]. *Ann Chir Plast Esthet. French* 2018;63(1):54-60.  
DOI: 10.1016/j.anplas.2017.09.008  
Epub 2017 Oct 26. PMID: 29107433.
- Burnier P, Niddam J, Bosc R, Hersant B, Meningaud JP. Indocyanine green applications in plastic surgery: A review of the literature. *J Plast Reconstr Aesthet Surg.* 2017;70(6):814-826.  
DOI: 10.1016/j.bjps.2017.01.020  
Epub 2017 Feb 20. PMID: 28292569.
- Executive Committee of the International Society of Lymphology. The diagnosis and treatment of peripheral lymphedema: 2020 Consensus Document of the International Society of Lymphology. *Lymphology.* 2020; 53(1):9.  
PMID: 32521126.
- José Luis Ciucci et al. Coordinación general de Enrique Angel Peralta.- 6° Consenso Latinoamericano para el Tratamiento del Linfedema: Guía de tratamiento. - 1a ed.- Ciudad Autónoma de Buenos Aires: Nayarit. 2017;55:140.
- Kayıran O, De La Cruz C, Tane K, Soran A. Lymphedema: From diagnosis to treatment. *Turk J Surg.* 2017;33(2):51-57.  
DOI: 10.5152/turkjsurg.2017.3870  
PMID: 28740950; PMCID: PMC5508242.
- López-Montoya LE, Pereira-de Godoy JM, y Guerreiro-Godoy M. de F. Evolución

- distinta de linfedema primario etapa II de miembros inferiores. Revista de la Facultad de Medicina. 2019;67(3):547-549. DOI: <https://doi.org/10.15446/revfacmed.-v67n3.66099>
10. López Montoya, Luis. El linfedema Explicado. Editorial Fenix. México 2018;1: 41-45
  11. Bundred N, Foden P, Todd C, et al. Increases in arm volume predict lymphoedema and quality of life deficits after axillary surgery: A prospective cohort study. Br J Cancer. 2020;123(1):17-25. DOI: 10.1038/s41416-020-0844-4
  12. Boyages J, Xu Y, Kalfa S, et al. Financial cost of lymphedema borne by women with breast cancer. Psychooncology. 2017; 26(6):849-855. DOI: 10.1002/pon.4239
  13. Bowman C, Piedalue KA, Baydoun M, Carlson LE. The quality of life and psychosocial implications of cancer-related lower-extremity lymphedema: A Systematic Review of the Literature. J Clin Med. 2020;9(10):3200. DOI: 10.3390/jcm9103200 PMID: 33023211.
  14. Greene AK, Goss JA. Diagnosis and staging of lymphedema. Semin Plast Surg. 2018;32(1):12-16. DOI:10.1055/s-0038-1635117
  15. Forte AJ, Boczar D, Huayllani MT, Lu X, Ciudad P. Lymphoscintigraphy for evaluation of lymphedema treatment: A systematic review. Cureus. 2019;11(12): 6363. DOI: 10.7759/cureus.6363 PMID: 31886094; PMCID: PMC6907718.
  16. Suami H, Heydon-White A, Mackie H, Czerniec S, Koelmeyer L, Boyages J. A new indocyanine green fluorescence lymphography protocol for identification of the lymphatic drainage pathway for patients with breast cancer-related lymphoedema. BMC Cancer. 2019;19(1): 985. DOI:10.1186/s12885-019-6192-1
  17. Koelmeyer LA, Borotkanics RJ, Alcorso J, et al. Early surveillance is associated with less incidence and severity of breast cancer-related lymphedema compared with a traditional referral model of care. Cancer. 2019;125(6):854-862. DOI: 10.1002/cncr.31873
  18. McDuff SGR, Mina AI, Brunelle CL, et al. Timing of lymphedema after treatment for breast cancer: When are patients most at risk?. Int J Radiat Oncol Biol Phys. 2019; 103(1):62-70. doi:10.1016/j.ijrobp.2018.08.036
  19. Johnson AR, Kimball S, Epstein S, Recht A, Lin SJ, Lee BT, James TA, Singhal D. Lymphedema incidence after axillary lymph node dissection: Quantifying the impact of radiation and the lymphatic microsurgical preventive healing approach. Ann Plast Surg. 2019;82(4S Suppl 3):234-241. DOI: 10.1097/SAP.0000000000001864 PMID: 30855393.
  20. Marshall MV, Rasmussen JC, Tan IC, et al. Near-infrared fluorescence imaging in humans with Indocyanine green: A review and update. Open Surgical Oncology Journal (Online). 2010;2(2):12-25. DOI: 10.2174/1876504101002010012
  21. Fujisawa Y, Nakamura Y, Kawachi Y, Otsuka F. A custom-made, low-cost intraoperative fluorescence navigation system with indocyanine green for sentinel lymph node biopsy in skin cancer. Dermatology. 2011;222(3):261-8. DOI: 10.1159/000327080 Epub 2011 Apr 19. PMID: 21502752.

© 2020 Montoya et al.; This is an Open Access article distributed under the terms of the Creative Commons Attribution License (<http://creativecommons.org/licenses/by/4.0>), which permits unrestricted use, distribution, and reproduction in any medium, provided the original work is properly cited.

*Peer-review history:*  
*The peer review history for this paper can be accessed here:*  
<http://www.sdiarticle4.com/review-history/62779>