



Polyaxial Locking Plate in Fractures of the Distal Radius

**Mostafa F. Mohamed^{1*}, Ali M. Emran¹, Osama A. Selim¹
and Mahmoud A. El Rosasy¹**

¹Department of Orthopedic Surgery, Tanta University, 17 Kafr El Sheikh Selim, Tanta, Egypt.

Authors' contributions

This work was carried out in collaboration among all authors. Author MFM designed the study, performed the statistical analysis, wrote the protocol and wrote the first draft of the manuscript. Authors AME and OAS managed the analyses of the study. Author MAER managed the literature searches. All authors read and approved the final manuscript.

Article Information

DOI: 10.9734/JAMMR/2020/v32i2230709

Editor(s):

(1) Dr. Mohamed Essa, Sultan Qaboos University, Oman.

Reviewers:

(1) Fred Mukolwe Kalande, Egerton University, Kenya.

(2) Farid Najd Mazhar, Iran University of Medical Sciences, Iran.

Complete Peer review History: <http://www.sdiarticle4.com/review-history/62103>

Review Article

Received 27 August 2020

Accepted 03 November 2020

Published 28 November 2020

ABSTRACT

Introduction: Volar locking plate represents the gold standard method of treatment of unstable distal end radius fractures.

Objectives: The Present study aimed to identify the functional and radiological outcomes of distal radius fractures treated by open reduction and internal fixation using polyaxial volar locking plate.

Patients and Methods: We reviewed 25 unstable distal end radius fractures that were operated in Orthopedic Department in Tanta University Hospital with polyaxial volar locking plates June 2018 to June 2019. The mean age of the patients was 40.8 ± 14.34 years (range 24 to 65) and the mean duration of follow-up was 8.61 ± 3.19 months (range 6 to 17). All of the patients underwent open reduction and internal fixation with polyaxial locking plate through over flexor carpi radialis approach. After three months, pain, tendon functions, ROM, hand grip as well as radial median and ulnar nerves functions were well assessed. X-rays were done to assure full fracture consolidation. At the end of follow up, clinical results were evaluated according to Quick DASH Score. Castaign radiological assessment score was used for radiological evaluation.

Results: There was a significant improvement in the functional indices from twelve weeks to the final follow-up. According to Castaign radiological assessment score 10 patients (40%) had

*Corresponding author: E-mail: mostafa.farouk345@gmail.com;

excellent results, 14 patients (56%) had good results and 1 patient (4%) had fair results, no patients had poor results at the final follow up. Compared the performance of the polyaxial locking plate to another monoaxial plate and reported an improved range of radial and ulnar deviation with the variable angle device but they use another plate system.

Conclusions: The use of polyaxial locking plates in treating unstable distal end radius fractures is associated with excellent to good functional results with minimal complications.

Keywords: Polyaxial locking plate; fractures; distal radius; ulnar nerves functions.

1. INTRODUCTION

The distal radius is one of the most commonly fractured bones in the body accounting for 8 – 15% of all broken bones [1]. Such fractures mainly affect the elderly population and they involve low energy trauma. However, in young adults, high energy trauma such as that resulting from vehicular traffic accidents [2], which present as shear and impacted fractures of the articular surface of the distal radius with displacement of the fragments [3].

A fracture of the distal radius is considered unstable by inability to resist displacement following anatomic reduction. Some of the more redundant factors of instability in the literature include fracture prereluction with the following radiographic features:

- Dorsal tilt greater than 20°.
- Radial inclination less than 15°.
- Radial shortening greater than 5 mm (or alternatively, resultant ulnar positive variance).
- Extension into the radiocarpal joint.
- Concomitant fracture of the ulna.
- Patient more than 60 years old or presence of osteoporosis [4,5].

Whereas a large number of these fractures are managed non-operatively, the number of patients who undergo surgical management is considerable [2].

The goals of surgical treatment include restoration of alignment, rotation, and angulation in both the coronal and sagittal planes for the extraarticular fractures and intraarticular fractures [6].

Maintenance of articular congruity, freeing joint range of motion and stable fixation reduce the incidence of osteoarthritis and help for earlier rehabilitation [7].

Volar locking plates mechanically bridge the bone and bear the load through the locking

construct, resulting in a lower incidence of failure. The subchondral placement of distal screws is essential to prevent a loss of correction and to achieve good functional results [8,9]. Experimental biomechanical evidence supporting their use with dorsally comminuted unstable distal radius fractures was recently published [10].

Goals in the application of volar plates include the accurate and safe subchondral placement of screws, combined with the achievement of true radial column support. In using a fixed-angle plate, this may be difficult to achieve because of variations in the size of the radius as well as variations in the location of the fracture lines, particularly the volar fracture lines [11].

Variable-angle screws allow adaptation of the plate position to volar fracture lines in both a proximal-to-distal plane and a radial-to-ulnar plane. This adaptation can be achieved by directing screws away from the joint [12].

2. PATIENTS AND METHODS

2.1 Patients

The study included 25 patients suffering from fractures of the distal radius admitted to Orthopedic Department in Tanta University Hospital. All patients were operated from June 2018 to June 2019.

The inclusion criteria for the study were as follows:

- Age: Skeletally mature patients group (>18) years old.
- Unstable extra articular fractures.
- Intra-articular fractures.

The exclusion criteria for the study were:

- Open fractures Gustilo and Anderson type II and III.
- Pathological fractures.

- Patients whose are unfit for surgery.

The age of the patients ranged from 24 to 65 with a mean of (40.8±14.34) years. Among 25 patients 16 were males (64%) while 9 were females (36%). Right dominant side was affected in 14 patients while 11 had the non-dominant side affected. The most common mode of trauma in this study was falling on out-stretched hand (44%) and falling from height (24%).

The fracture was classified according to Frykman's classification there were seven patients Frykman's type III, seven patients type VII, six patients type VIII, three patients type IV, one patient type I and one patient type V.

2.2 Methods

2.2.1 Preoperative diagnosis and assessment

- History.
- Clinical examination.
- Radiological evaluation.

For preoperative assessment of fracture type and degree of displacement of the fragments, the anteroposterior and lateral views of the wrist and CT scan were obtained.

3. METHODS OF TREATMENT

All patients were treated by open reduction and internal fixation (ORIF) by using the Polyaxial 2.4-mm distal radius locking plate.

3.1 First Aid Treatment

The fractured limb was splinted in flexion elbow and neutral position of wrist to relieve pain till time of surgery. Analgesic and anti-edematous

drugs were given as required. Patients then were admitted and scheduled for surgery.

3.2 Anesthesia

Under general or local IV anesthesia and after prophylactic IV antibiotics were given a tourniquet was inflated. The surgical field was disinfected and prepared in the formal manner.

4. BASIC PROCEDURES

All fractures were fixed using a volar approach to the distal radius as described by Orbay over flexor carpi radialis tendon [13]. The skin incision is made directly over the course of the FCR tendon and is 8 to 10 cm long (Fig. 1).

The dissection is taken down to the surface of the distal radius by developing the space between the flexor pollicis longus and the radial septum. The radial origins of the most distal fibers of the flexor pollicis longus muscle are released for greater exposure.

The pronator quadratus muscle and the anterior wrist capsule are then exposed after blunt dissection and then is mobilized by releasing its distal and lateral borders with an L-shaped incision (Fig. 2). It is then lifted from its bed by subperiosteal dissection, exposing the fracture site.

After exposure and debridement of the fracture site, the fracture was reduced and provisionally fixed under C-Arm using k-wires. Extra articular fractures were reduced by simple traction and slight palmar flexion of the wrist and manual manipulation. In intra articular fractures large fragments were be manipulated, reduced and preliminary fixed by wires (Fig. 3).

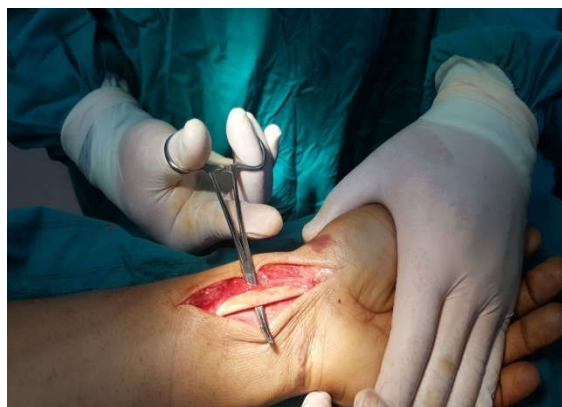

Fig. 1. Flexor carpi radialis tendon after sheath release

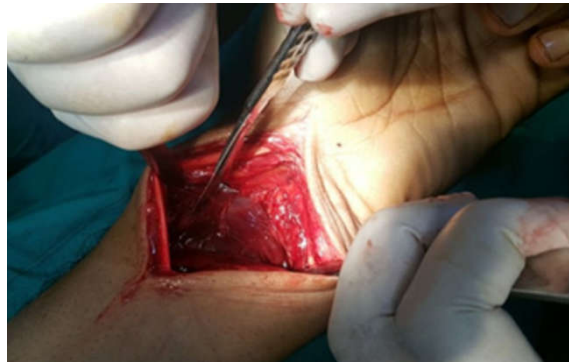

Fig. 2. Pronator quadratus exposed and an I-shaped incision is made to elevate it

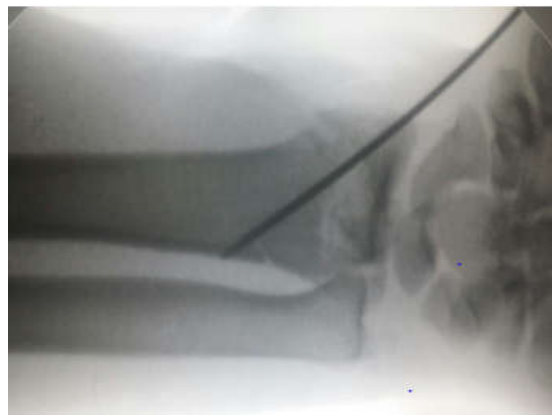

Fig. 3. Preliminary fixation of large articular fragments

4.1 Plate Position

The plate should be positioned on the distal radius proximal to the Watershed line. If placed properly, K-wires inserted in it to insure the position. The plate is designed to be elongated in its ulnar side as the volar surface of the ulnar column is more distal than radial column. The position of plate is confirmed by C-arm (Fig. 4a).

The plate may be positioned more distally to cover the volar fracture line or more ulnar if there was a sagittal plane fracture line in the ulnar portion of distal radius. A screw is inserted in the oval non-locking hole of the plate which permits fine adjustment of the plate position either proximally or distally. At this point, the plate is used as a buttress for the lunate facet fragment (Fig. 4b).

4.2 Wound Closure

The pronator quadratus was repaired over the plate if it was repairable. The subcutaneous layer is closed and the skin is closed with simple interrupted sutures starting at the zigzag portion

of the incision. And the patient is put in a splint making sure that the MPJ and the fingers are free.

4.3 Post-Operative and Rehabilitation

Post-operative treatment was described for patients with anti-edematous, NSAID and antibiotic. Early active fingers and MP exercises were encouraged. The splint was removed at one week and patients were allowed to wear wrist brace for two weeks. Patients were instructed to remove the brace and start gentle active wrist and finger exercises.

4.4 Follow Up

At the twelve weeks, full evaluation was done including wrist ROM, pain, tendon functions to evaluate presence of tenosynovitis or tendon rupture if any as well as median nerve functions. X-rays were done to assure full fracture consolidation. At the end of follow up, clinical results were evaluated according to Quick DASH Score [14]. Radiological evaluation was done according to Castaign radiological assessment score [15].




Fig. 4.

4.5 Statistical Analysis

Two types of statistical analysis were done:

- Descriptive statistics: e.g. percentage (%), mean and standard deviation (SD).
- Analytic statistics: e.g. chi-square Test. P-value of <0.05 is considered statistically significant.

5. RESULTS

Twenty five patients were included in this study according to inclusion criteria. The minimum follow up period was 6 months and the maximum

was 17 months with a mean of 8.61 ± 3.19 months. Time before operation ranged from 2 days to 14 days, the mean time was (5.2) days. Range of motion was evaluated at the end of follow up period (Table 1).

At the end of the follow up period, according to Quick DASH scoring system [14], 10 patients (40%) had excellent results (scores between 0-11), 12 patients (48%) had good results (scores between 12-22) and 3 patients (12%) had fair results (scores between 23-33), no patients had poor results (Table 2). The score ranged from 0 to 24 in the studied patients' group with a mean of (14.4).

Table 1. Range of motion at the end of follow up period

Range of movement	Range	Mean	±	SD
Dorsiflexion	40 - 75	64.80	±	9.73
Palmar flexion	45 - 80	71.28	±	7.75
Pronation	65 - 85	74.52	±	4.53
Supination	55 - 85	77.28	±	7.23
Radial deviation	11 - 20	17.36	±	2.61
Ulnar deviation	30 - 40	36.64	±	2.38

Table 2. Relation between dominant hand and final functional score

Side	Quick DASH score							
	Excellent		Good		Fair		Total	
	N	%	N	%	N	%	N	%
Non-dominant	1	10.0	7	58.3	3	10.0	11	44.0
Dominant	9	90.0	5	41.7	0	0.0	14	56.0
Total	10	100.0	12	100.0	10	100.0	25	100.0
Chi-square	X^2		9.510					
	P-value		0.009*					

Radiological parameters were evaluated at the end of follow up period and were as follow:

Ulnar deviation 30 - 40 36.64 ± 2.38

5.1 Inclination

Inclination angle (frontal tilt) ranged from 17° to 24° with a mean of 20.36°±2.5.

All affected dominant hand patients achieved excellent and good results while the non-dominant there were 11 patients (44%) achieved good and poor results and this was found to be significant (P <0.05) (Table 2.)

5.2 Volar Tilt

Volar (sagittal) tilt ranged from 7° to 14° with a mean of 10.32°±2.26.

Regarding to the fracture classification, There was a statistically insignificant correlation between fracture type according to Frykman's classification system and the final clinical (P value = 0.209) and radiological score (P value =0.099).

5.3 Radio-Ulnar Joint Line

Radio-ulnar joint line distance ranged from -2 mm to 2 mm with a mean of -0.56 mm ±1.35.

A non-significant difference was found between the functional or radiological end result and the interval between fracture and operation (p value>0.05).

5.4 Radio Carpal-Joint Line

16 patients (64%) had a regular joint line, 6 patients (24%) had narrowed joint line, and 3 patients (12%) had a radiological signs of arthritis.

Eight patients had an associated ulnar styloid fracture, their mean score was 6.62±1.06. Seventeen patients did not have an associated ulnar styloid fracture and their mean score was 6.06±0.89 (Table 3).

According to Castaign radiological assessment score [15] 10 patients (40%) had excellent results.

There was high significant correlation between the functional result and the radiological results (p-value<0.001). Patients with excellent radiological result achieved excellent functional end result, patients with good radiological result achieved excellent and good functional results and none of patients with poor radiological result achieved excellent functional result (Table 4).

- Range of movement Range Mean ± SD
- Dorsiflexion 40 - 75 64.80 ± 9.73
- Palmar flexion 45 - 80 71.28 ± 7.75
- Pronation 65 - 85 74.52 ± 4.53
- Supination 55 - 85 77.28 ± 7.23
- Radial deviation 11 - 20 17.36 ± 2.61

Table 3. Relation between the presence of ulnar styloid fracture and final clinical score

Associated injuries	Quick DASH score							
	Excellent		Good		Fair		Total	
	N	%	N	%	N	%	N	%
Ulnar styloid	4	40.0	3	25.0	1	33.3	8	32.0
Without ulnar styloid	6	60.0	9	75.0	2	66.7	17	68.0
Total	10	100.0	12	100.0	3	100.0	25	100.0
Chi-square	X ²	0.567						
	P-value	0.753						

Table 4. Relation between clinical or functional results and radiological results

Castaing score	Quick DASH score							
	Fair		Good		Excellent		Total	
	N	%	N	%	N	%	N	%
Excellent	0	0.0	1	4.0	9	36.0	10	40.0
Good	2	8.0	11	44.0	1	4.0	14	56.0
Fair	1	4.0	0	0.0	0	0.0	10	4.0
Total	3	12.0	12	48.0	10	40.0	25	100.0
Chi-square	X ²	24.357						
	P-value	<0.001**						

In our study two patients had numbness in hand along median nerve distribution underwent carpal tunnel release during follow up period. One patient had a tourniquet palsy which was resolved after one month of physiotherapy. Tourniquet palsy which was resolved after one month of physiotherapy.

One patient suffered from delayed wound healing. This resolved completely after one month. Two patients had superficial wound infections that were resolved with regular dressings and antibiotic administration for two weeks. One patient had screw misplacement in radio-ulnar joint that remains asymptomatic at the final follow up period.

6. DISCUSSION

Polyaxial volar locking plates are biomechanically sound for the management of intra-articular fractures of the distal radius in a cadaveric study. Sascha Rausch et al, found that these plates have higher construct stiffness and superior properties under cyclic loading than monoaxial fixed angle plates [16].

These plates enable insertion of screws at variable angles and allow secure subchondral placement of distal screws which is more difficult in fixed angle plates [10,17].

The aim of the work in this study was to evaluate the outcome of management of unstable distal radius fractures using polyaxial volar locking plate.

In This study there were 25 patients with unstable distal end radius fractures who underwent open reduction and internal fixation using polyaxial locking plate. The patients' age ranged from 24 to 65 years old with mean of (40.8±14.34). There were 16 males and 9 females.

The most common mode of trauma in this study was falling on out-stretched hand (44%) and falling from height (24%).

The minimum duration of follow-up in our study was six months. Distal end radius fractures achieve the majority of their grip strength and movement in six months as reported by MacDermid et al. [18].

At the end of the follow up period, according to Quick DASH scoring system [14], 10 patients

(40%) had excellent results (scores between 0-10), 12 patients (48%) had good results (scores between 12-22) and 3 patients (12%) had fair results (scores between 23-33), no patients had poor results. The score ranged from 0 to 24 in the studied patients' group with a mean of (14.4).

Figl et al. reported excellent results in 36% of patients, good results in 51%, and fair results in 13%. Jagodzinski et al. [19], reported a mean Quick DASH (disabilities of the arm, shoulder, and hand) score of 18.2 in patients treated with Poly axial volar locking plate [20]. In this results excellent results reported 40%, good results were 48 % and fair results were 12.0% which is comparable to their results.

In a study made by Kenny Kwan et al. on 75 patients had distal radius fractures managed by 2.4 mm distal radius plates, they found that an excellent or good result was obtained in 96% of patients according to modified Green and O'Brien score [21].

These results are not truly comparable with those of the current study as a different scoring system was used in the evaluation of the results. On other hand, there was a strong correlation between Green and O'Brien score that we used and the DASH score was found by Kwok IHY et al. in their study [22].

The range of movement of the wrist was evaluated at the end of follow up period. Dorsiflexion ranged from 40 to 75 degrees with a mean of $64.8^{\circ} \pm 9.73$. While palmar flexion ranged from 45 to 80 degrees with a mean of $71.28^{\circ} \pm 7.75$.

Supination ranged from 55 to 85 degrees with a mean of $77.28^{\circ} \pm 7.23$, while pronation from 65 to 85 degrees with a mean of $74.52^{\circ} \pm 4.53$. Radial deviation ranged from 11 to 20 degrees with a mean of $17.36^{\circ} \pm 2.61$, while ulnar deviation from 30 to 40 with a mean of $36.64^{\circ} \pm 2.38$. These values correspond well with the functional daily requirements.

By comparing the results of this study and the study done by Khatri K et al. [11], this study was found to have comparable results. They used Polyaxial volar locking plate in 23 unstable distal end radius fractures. According to Gartland and Werley excellent results were reported in 65.2% cases, while good results were present in 35% cases. The mean flexion was $71.91^{\circ} \pm 8.08$, the mean extension was $76.95^{\circ} \pm 5.70$, the mean

pronation was $77.65^{\circ} \pm 6.01$ and the mean supination was $81.86^{\circ} \pm 6.28$.

Spiteri et al. found that postoperative range of motion was variable and grip strength was of 71% of the uninjured contralateral side with the use of Polyaxial volar rim plate in their study [23].

Vlcek et al. compared the performance of the Polyaxial locking plate to another Monoaxial plate and reported an improved range of radial and ulnar deviation with the variable angle device but they use another plate system [24].

At the end of the follow up period, according to Castaign radiological assessment score [15], 10 patients (40%) had excellent results (scores between 7-8), 14 patients (56%) had good results (scores between 5-6) and 1 patient (4%) had fair results (scores between 3-4), no patients had poor results. The score ranged from 4 to 8 in the studied patients' group with a mean of (6.24).

6.1 Inclination

At the end of follow up period, inclination angle (frontal tilt) ranged from 17° to 24° (mean was $20.36^{\circ} \pm 2.53$).

6.2 Volar Tilt

At the end of follow up period, volar (sagittal) tilt ranged from 7° to 14° (mean was $10.32^{\circ} \pm 2.26$).

By comparing the results of this study and the study done by Khatri K et al. our study was found to have comparable results. Radial length mean was $11.84 \text{ mm} \pm 2.04$, radial inclination mean was $22.89^{\circ} \pm 2.64$ and the volar angulation mean was $5.21^{\circ} \pm 2.72$ [11].

Sim JC et al. analyzed the results in 45 cases treated by Polyaxial volar locking plate. At the end of follow up period the mean radial length was 11.8 mm (9.2-14.3), radial inclination was 22.0° (15.9-31.6), and volar tilt was 8.7° (1.3-15.8). The results of the study are radial Inclination: ranged from 17° to 24° (mean was $20.36^{\circ} \pm 2.53$) and Volar tilt ranged from 7° to 14° (mean was $10.32^{\circ} \pm 2.26$) which are comparable to these results [25,26].

6.2.1 Ulnar styloid fractures

Eight patients had an associated ulnar styloid fracture, their mean score was 6.62 ± 1.06 . None

of them received fixation. There was no statistical significance regarding the final score between patients with associated ulnar styloid and those without.

They found that no significant difference was found in Patient-Rated Wrist Evaluation scores, range of motion, grip strength, visual analogue scale pain scores, ulnar-sided wrist pain and distal radio-ulnar joint instability between patients with and without an ulnar styloid process fracture after 1 year of follow-up. Moreover, no significant differences were found between ulnar styloid base and non-base fractures.

6.2.2 Relation between radiological and functional results

In our study there was a high significant correlation between radiological and functional end results. Patients with excellent radiological result achieved excellent functional end result, patients with good radiological result achieved excellent and good functional results and none of patients with poor radiological result achieved excellent functional result.

There are many studies support our results as in Sachin Y Kale et al. They found that radiological parameters have an effect on functional outcome in their study at six month of follow up. The more the number of radiological parameters affected the poorer is the functional outcome [27].

7. CONCLUSION

- (i) The newest concept the volar locking plates with angle stable screws are becoming widely used. Treatment of distal radius fractures with a volar polyaxial locking plate fixation is safe and effective. Using these plates is associated with excellent and good functional outcome with significant reduction of hardware complication.
- (ii) Fixation of styloid process is not a pre requisite and does not functionally affect the outcome.

CONSENT

It is not applicable.

ETHICAL APPROVAL

It is not applicable.

COMPETING INTERESTS

Authors have declared that no competing interests exist.

REFERENCES

1. Oc Y, Kilinc BE, Armagan R, Kara A, Kanar M, Osman Eren OT. Volar locking plating treatment results in fragmented intraarticular distal radius fractures. *Ser J Exp Clin Res.* 2016;17(1):27-33.
2. Arora R, Gabl M, Gschwentner M, Deml C, Krappinger D, Lutz M. A comparative study of clinical and radiologic outcomes of unstable colles type distal radius fractures in patients older than 70 years: Nonoperative treatment versus volar locking plating. *J Orthop Trauma.* 2009;23(4):237-42.
3. Lozano-Calderon SA, Doornberg J, Ring D. Fractures of the dorsal articular margin of the distal part of the radius with dorsal radiocarpal subluxation. *J Bone Joint Surg Am.* 2006;88:1486-1493.
4. Porrino JA, Maloney E, Scherer K, Mulcahy H, Ha AS, Allan C. Fracture of the distal radius: Epidemiology and pre-management radiographic characterization. *AJR.* 2014;203:551-559.
5. Tahirian MA, Javdan M, Nouraei MH, Dehghani M. Evaluation of instability factors in distal radius fractures. *J Res Med Sci.* 2013;18:892-6.
6. Senehi R, Luo TD, Marquez-Lara A, Aneja A, Beard HR, Carroll EA. Use of volar plate for indirect coronal plane reduction in an intraarticular distal radius fracture. *J Orthop Trauma.* 2017;31:S39- S41.
7. Wong KK, Chan KW, Kwok TK, Mak KH. Volar fixation of dorsally displaced distal radial fracture using locking compression plate. *J Orthop Surg.* 2005;13(2):153-157.
8. Egol K, Walsh M, Tejwani N, McLaurin T, Wynn C, Paksima N. Bridging external fixation and supplementary Kirschner wire fixation versus volar locked plating for unstable fractures of the distal radius: A randomized, prospective trial. *J Bone Joint Surg Br.* 2008;90(9):1214-1221.
9. Osada D, Viegas SF, Shah MA, Morris RP, Patterson RM. Comparison of different distal radius dorsal and volar fracture fixation plates: A biomechanical study. *J Hand Surg Am.* 2003;28(1):94-104.
10. Khamisy S, Weil YA, Safran O, Liebergall M, Mosheiff R, Khoury A. Outcome of dorsally comminuted versus intact distal radial fracture fixed with volar locking plates. *Injury Int J Care injured.* 2011;42:393-396.
11. Ross M, Heiss-Dunlop W, Slutsky DJ. Volar angle stable plating for distal radius fractures; 2010.
12. Khatri K, Sharma V, Farooque K, Tiwari V. Surgical treatment of unstable distal radius fractures with a volarvariable-angle locking plate: Clinical and radiological outcomes. *Arch Trauma Res.* 2016;5(2):e25174.
13. Orbay JL, Badia A, Indriago IR, Infante A, Khouri RK, Gonzalez E, et al. The extended flexor carpi radialis approach: A new perspective for the distal radius fracture. *Tech Hand Up Extrem Surg.* 2001;5(4):204-211.
14. Sadighi A, Bazavar M, Moradi A, Eftekharsadat B. Outcomes of percutaneous pinning in treatment of distal radius fractures. *Pak J Biol Sci.* 2015;13(14):706-710.
15. Pérez RL, Vera JP, Gabaldón BP, Baeza MC, Almodóvar JL. Prognostic factors in the treatment of distal radial fractures: Volar plate vs. external fixation. *Rev Esp Cir Ortop. Traumatol.* 2008;52:300-5.
16. Grewal R, Perey B, Wilmink M, Stothers K. A randomized prospective study on the treatment of intraarticular distal radius fractures: Open reduction and internal fixation with dorsal plating versus mini open reduction, percutaneous fixation and external fixation. *J Hand Surg Am.* 2005;30:764-772.
17. Hoffmeier KL, Hofmann GO, Muckley T. The strength of polyaxial locking interfaces of distal radius plates. *Clin Biomech.* 2009;24:637-641.
18. MacDermid JC, Roth JH, Richards RS. Pain and disability reported in the year following a distal radius fracture: A cohort study. *BMC Musculoskelet Disord.* 2003;4:24.
19. Figl M, Weninger P, Liska M. Volar fixed-angle plate osteosynthesis of unstable distal radius fractures: 12 months results. *Arch Orthop Trauma Surg.* 2009;129:661-669.
20. Jagodzinski NA, Singh T, Norris R, Jones J, Power D. Early results of a variable-angle volar locking plate for distal radius fractures: A bi-centre study. *Orthopaedic Proceedings;* 2012.

21. Kwan K, Lau TW, Leung F. Operative treatment of distal radial fractures with locking plate system— A prospective study. *International Orthopaedics*. 2011;35(3):389-394.
22. Kwok IHY, Leung F, Yuen G. Assessing results after distal radius fracture treatment: A comparison of objective and subjective tools. *J Geriatr Orthop Surg Rehabil*. 2011;2(4):155-160.
23. Spiteri M, Ng W, Matthews J, Power D. Functional outcome of fixation of complex intra-articular distal radius fractures with a variable-angle distal radius volar rim plate. *J Hand Microsurg*. 2017;9(1):11-16.
24. Vlcek M, Landor I, Visna P, Vavrik P, Sindelarova J, Sosna A. Multidirectional screw fixation in the treatment of distal radius fractures using angle-stable plates. *Acta Chir Orthop Traumatol Cech*. 2011;78:27-33. (In Czech)
25. Sim JC, Ha SS, Hong KD, Kim TH, Sung MC. Treatment of fractures of the distal radius using variable-angle volar locking plate. *J Korean Fract Soc*. 2015;28(1):46-52.
26. Mulders MAM, Fuhri Snethlage LJ, De Muinck Keizer RO, Goslings JC, Schep NWL. Functional outcomes of distal radius fractures with and without ulnar styloid fractures: A meta-analysis. *J Hand Surg Eur*. 2018;43(2):150-157.
27. Kale SY, Bhor P, Salunkhe R, Devda AV. Correlation between radiological and functional outcome of post operative intra articular distal end radius fracture. *Ind J Appl Basic Med Res*. 2016;5(3):906-909.

© 2020 Mohamed et al.; This is an Open Access article distributed under the terms of the Creative Commons Attribution License (<http://creativecommons.org/licenses/by/4.0>), which permits unrestricted use, distribution, and reproduction in any medium, provided the original work is properly cited.

Peer-review history:

The peer review history for this paper can be accessed here:

<http://www.sdiarticle4.com/review-history/62103>