



Clinico-histopathological Assessment of Patients Undergoing Thyroidectomy

**Rasool Bux Behan¹, Agha Taj Mohammed¹, Bilal Rasool¹
and Mujeeb-Ur-Rehman Laghari^{1*}**

¹Department of General Surgery, Liaquat University of Medical and Health Sciences (LUMHS),
Jamshoro, Sindh Pakistan.

Authors' contributions

This work was carried out in collaboration among all authors. Authors RBB and ATM designed the study and wrote the first draft of the manuscript. Authors BR and MURL managed the analyses and literature searches of the study. All authors read and approved the final manuscript.

Article Information

DOI: 10.9734/JPRI/2020/v32i630452

Editor(s):

(1) Dr. Carlos M. Contreras, Unidad Periférica Xalapa, Instituto de Investigaciones Biomédicas, UNAM, Instituto de Neurootología, Universidad Veracruzana, Mexico.

Reviewers:

(1) Ashish Dhakal, Kathmandu University Hospital, Nepal.

(2) Pietro Giorgio Calò, University of Cagliari, Italy.

Complete Peer review History: <http://www.sdiarticle4.com/review-history/53764>

Original Research Article

Received 02 October 2019

Accepted 07 January 2020

Published 15 May 2020

ABSTRACT

Objective: To determine the clinical presentation and histopathological evaluation of patients undergoing thyroidectomies at tertiary care Hospital.

Methodology: This cross-sectional study was done at department of general surgery of LUMHS/Jamshoro. Duration of the study was 1 year from October 2017 to September 2018. All the cases with a diagnosis of thyroid disorder and underwent thyroidectomy were selected and above 25 years of the age were included. All the surgeries were carried out by senior surgeons along with the cooperation of the ENT surgeons. After surgeries specimens of all the cases were sent to the diagnostic laboratory for the histological assessment. Data was collected via self-made proforma.

Results: Of 58 patients majority i.e. 43.10% were found with age group of 35-44 years. Females found in the majority 63.80%. The swelling was noted among all of the cases, followed by pain, difficulty in swallowing, difficulty in breathing and

others 8.62%, 10.34%, 20.68% and 25.68% respectively. Adenomatous goiter was the most common histopathological finding in 82.75% cases, papillary carcinoma was found 8.62%, follicular carcinoma was only in one case and anaplastic carcinoma was also in 1 case.

*Corresponding author: E-mail: doctormujeeb786@gmail.com, drmsarain@gmail.com;

Conclusion: Swelling, difficulty in swallowing and difficulty in breathing were the most common clinical features. Adenomatous goiter was the most common histological finding and papillary carcinoma was the commonest malignancy.

Keywords: Thyroidectomy; clinical presentation; histopathology.

1. INTRODUCTION

Thyroid disorder is one of the commonest events, seen in the clinical side mostly benign in nature. Thyroid nodules have been described on neck palpation estimated 4 to 7% of population and 30 to 50% in the peoples through [1,2]. Dietary iodine deficiency has been associated with thyroid malignancy [3] and northern areas of Pakistan are known for endemic iodine deficiency goiter and hence the high frequency of goiter in local population [4].

According to UNICEF (1998) report, 70% of the total population in Pakistan is at risk of iodine deficiency disorder. Other causes include heredity, neoplasia, inflammations, drugs and exposure to radiations [5]. Though the prevalence of thyroid cancer is comparatively rare, it is the commonest malignancy of the endocrine throughout the world. As well as international prevalence differs considerably, a properly consistent male to female ratio of 1:3 has been observed almost in all the areas geographically and ethnic group [6].

Incidence of thyroid cancer has been elevated between 1973 and 2002 in the most population throughout the world. It has been observed that ultimately it is increases by 48.0% in the males and 66.7% in the females. Recently, according to age international prevalence of the thyroid cancer varied 5-folds from 1998–2002 by region geographically in men and about 10 fold in women [7]. Management modalities are primarily, anti-thyroid medicines and surgeries. Commonest surgical procedure (Subtotal thyroidectomy) being carried out for multinodular goiters, because it is safe and easier to perform, having short time consuming and with less operative and postoperative complications, particularly damage the recurrent laryngeal nerve and para-thyroids. It is involved in the removing of the majority of the diseased thyroid tissue along with the isthmus leaving behind a remains of approximately 4–8 g on every side [8,9].

Thyroid carcinoma has a reported frequency of 1.2% in Pakistan, of all reported malignancies

with more prevalence in females and a female to male ratio of 2.6:1 [10]. The frequency of the thyroid malignancy reported 0.9% to 13% from different parts of the world [11]. Therefore this study has been conducted to determine the clinical presentation and histopathological evaluation in patients underwent thyroidectomy at tertiary care Hospital.

2. MATERIALS AND METHODS

This prospective case series study was done at department of general surgery of LUMHS/ Jamshoro. Duration of the study was 1 year from October 2017 to September 2018. All the cases with the diagnosis of thyroid disorder and underwent thyroidectomy above 25 years of age and either of genders were included in the study. Complete clinical examination and routine laboratory investigations along with ultrasound were carried out. Informed consent was taken from each patient regarding risks of surgeries and complications. All the surgeries were carried out by senior surgeon minimum experience of 10 years with the cooperation of the ENT surgeons. After surgeries specimens of all the cases were sent to the diagnostic laboratory for the histological assessment. All data were entered in the predesigned proforma and was analyzed in the SPSS version 16.

3. RESULTS

In this study majority of the cases i.e. 43.10% were found with age group of 35-44 years, followed by 36.20% with age group of 45-54 years and 13.79% cases were between 25-34 years of the age. Female were found in the majority 63.80% as compared to males 36.20%. Thyroid disorder history less than 5 years was in 51.72% cases and more than 5 years was in 48.28% of the patients Table 1.

According to the clinical presentation, the swelling was noted among all of the patients, followed by pain, difficulty in swallowing, difficulty in breathing and others were found with the percentage of 8.62%, 10.34%, 20.68% and 25.68% respectively Fig. 1.

Table 1. Demographic data of patients (n = 58)

Basic characteristics	Numbers	Percentage
Age (years)		
25-34	08	13.79%
35-44	25	43.10%
45-54	21	36.20%
>55	04	06.89%
Gender		
Male	21	36.20%
Female	37	63.80%
Duration of illness		
< 5 years	30	51.72%
> 5 years	28	48.28%

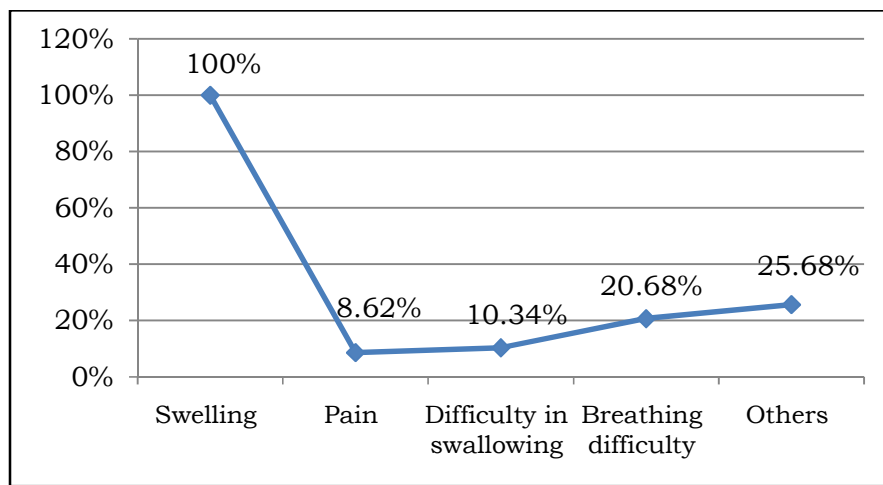


Fig. 1. Clinical presentation
(n = 58)

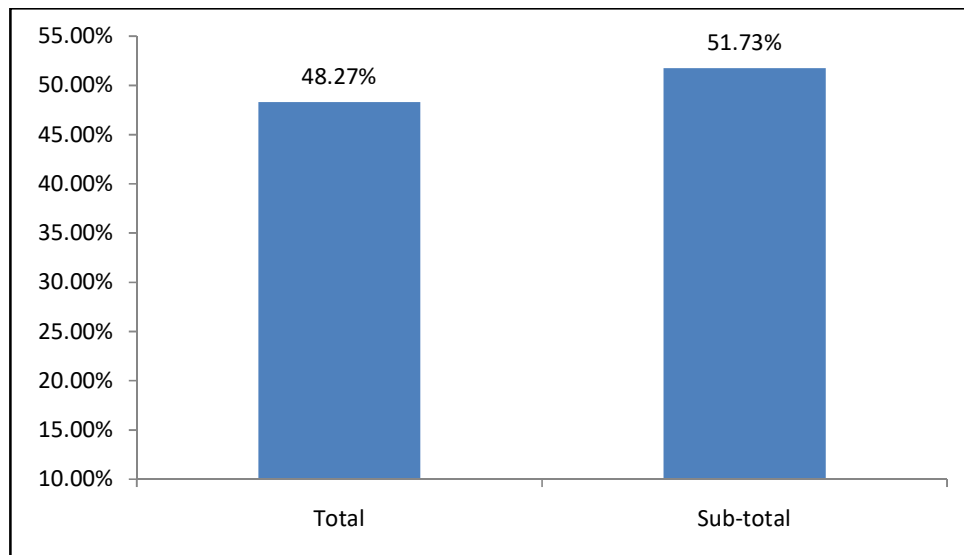


Fig. 2. Type of thyroidectomy
(n = 58)

Table 2. Histopathological assessment (n = 58)

Histopathology	Frequency (%)
Adenomatous goiter	48(82.75%)
Papillary carcinoma	05(8.62%)
Follicular carcinoma	01(1.72%)
Anaplastic carcinoma	01(1.72%)
Others	02(3.44%)

Out of total cases, 48.27% underwent total thyroidectomy, while remaining 51.73% underwent subtotal thyroidectomy Fig. 2.

On the histopathological assessment, adenomatous goiter was most common 82.75%, papillary carcinoma was found 8.62%, follicular carcinoma was in one patient and anaplastic carcinoma was also in one case, results show in Table 2.

4. DISCUSSION

Thyroid disorder is the commonest lesions are fairly common worldwide and are commonly encountered in clinical practice. Thyroid lesions may be developmental, inflammatory, hyperplastic and neoplastic [12]. This study was done to evaluate the histopathological assessment in patients underwent thyroidectomies. In this study, the majority of the cases were found with age group of 35-44 years and females were commonest. Similarly, Gupta A et al. [12] reported that the big prevalence of 51% of the thyroid enlargement noted between the age of 21-40 years with the female's gender predominated (77%). On the other hand Singh et al. [13] reported that the range of age 12 to 80 years and mean age 47 years. Islam et al. [14] demonstrated that most cases were between the age of 21 to 40 years. This gender difference may due to the fact that thyroid enlargement in female due to occurrence receptors of estrogen in thyroid tissues [15].

In this study according to the clinical presentation swelling was noted in 100% of the cases, following by pain, difficulty in swallowing, difficulty in breathing and others were found with the percentage of 8.62%, 10.34%, 20.68% and 25.68% respectively. In the comparison of our study, Gupta et al. [12] demonstrated that totally cases presented by swelling of the neck and some cases 3% had symptoms of the cervical lymphadenopathy, dysphagia in 1% cases, dyspnea and hoarseness was also in one case respectively as well as findings of our study. on

the other hand Prakash et al. [16] mentioned that swelling of the thyroids were in the 95.55% patients. Similarly Sachdeva et al. [17] stated that 90% cases had thyroid swelling, in 33.33% dysphagia and dyspnea was in 26.66% patients. Godinho-Matos et al. [18] reported that neck swelling was 100%, 4% cases had dysphagia, 3% had dyspnea, 8% vases had complaint of pain and hoarseness of voice was only 3% cases.

In this study out of all cases, 48.27% underwent total thyroidectomy, while remaining 51.73% underwent subtotal thyroidectomy. On the other hand, Sheik et al. [19] done total thyroidectomies and reported that the total thyroidectomy is the safe surgical technique and with the major advantage of fewer chances of recurrence. But we had performed both techniques according to need.

In this study adenomatous goiter was most common 82.75%. Follicular carcinoma in 1 case and anaplastic carcinoma was also in one case. Similarly, Sushel et al. [20] found comparable histological findings as; from 125 cases adenomatous goiter was commonest in 68% cases, follicular adenoma 27.1% and lymphocytic thyroiditis in 2% cases. We found papillary carcinoma 8.62%. Manzoor et al. [21] reported that papillary carcinoma was in the majority of the cases and follicular carcinoma 13.04 % cases. Benzarti et al. [22] stated that 9.5% of malignancy in thyroid disorder cases. Several other studies also mentioned that the papillary carcinoma was the commonest malignancy followed by follicular malignancy [21,23].

5. CONCLUSION

In this study concluded that the swelling, difficulty in swallowing and difficulty in breathing are the most common clinical features. Adenomatous goiter was the most common histological finding and commonest malignancy was the papillary carcinoma.

CONSENT AND ETHICAL APPROVAL

As per university standard guideline participant consent and ethical approval has been collected and preserved by the authors.

COMPETING INTERESTS

Authors have declared that no competing interests exist.

REFERENCES

1. Hanumanthappa MB, Gopinathan S, Suvarna R, Guruprasad Rai D, Shetty G, Shetty A, et al. Frequency of malignancy in multi-nodular goitre: A prospective study at a tertiary academic centre. *Jour Clin Diag Research*. 2012;6(2):267-70.
2. Pang HN, Chen CM. The frequency of cancer in nodular goitres. *Ann Acad Med Singapore*. 2007;36:241-3.
3. Lawal O, Agbakwuru A, Olayinka OS, Adelusola K. Thyroid malignancy in endemic nodular goitres: Prevalence, pattern and treatment. *Eur J Surg Oncol*. 2001;27(2):157-61.
4. Khan MA, Saleem SM, Zafarullah. Frequency of tumor in thyroid specimen after subtotal thyroidectomy in multi nodular goiter *RMJ*. 2015;40(1):59-61.
5. Bhatti ZA, Phulpoto JA, Shaikh NA. Multi-nodular goiter; frequency of malignancy malignancy. *Professional Med J*. 2013; 20(6):1035-1041.
6. Iftikhar A, Naseeb AK, Khwaja A, Mati H, Karim K, Hameeda N. Patterns of differentiated thyroid cancer in Baluchistan Province of Pakistan: Some initial observations. *The Medical Journal of Malaysia*. 2011;66(4):322-5.
7. Kilfoy BA, Zheng T, Holford TR, et al. International patterns and trends in thyroid cancer incidence, 1973-2002. *Cancer Causes Control*. 2009;20(5):525-31.
8. Sheikh IA, Waleem SS, Haider IZ, Haroon A, Ashfaq M. Total thyroidectomy as primary elective procedure in multinodular thyroid disease. *J Ayub Med Coll Abbottabad*. 2009;21(4):57-9.
9. Rosto L, Avenia N, De Palma M, Gulino G, Nasi PG, Pezzulo L. Complications of total thyroidectomy; Incidence, preventing and treatment. *Chir Ital*. 2000;54:635-42.
10. Shah SH, Muzaffar S, Soomro IN, Hasan SH. Morphological pattern and frequency of thyroid tumors. *J Pak Med Assoc*. 1999;49(6):131-3.
11. Sachmechi I, Miller E, Varatharajah R, Chernys A, Carroll Z, Kissin E, et al. Thyroid carcinoma in the single cold nodules and in the cold nodules of multi-nodular goitres. *Endocr Pract*. 2000; 6(1):5-7.
12. Gupta A, Jaipal D, Kulhari S, Gupta N. Histopathological study of thyroid lesions and correlation with ultrasonography and thyroid profile in western zone of Rajasthan, India. *International Journal of Research in Medical Sciences*. 2016;4(4): 1204-8.
13. Singh P, Chopra R, Calton N, Kapoor R. Diagnostic accuracy of fine needle aspiration cytology of thyroid lesions. *Journal of Cytology*. 2000;17(3):135-9.
14. Islam R, Ekramuddaula AFM, Alam MS, Kabir MS, Hossain D, Alauddin M. Frequency & pattern of malignancy in solitary thyroid nodule. *Bangladesh J of Otorhinolaryngology*. 2009;15(1):1-5.
15. Krukowski ZH. The thyroid gland and thyroglossal tract. In: Williams NS, Bulstrode CJK, O'Connell PR, eds. *Bailey & Love's short practice of surgery*. 24th ed. London. Hodder Education. 2004;776-804.
16. Psarras A, Papadopoulos SN, Livadas D, Pharmakiotis AD, Koutras DA. The single thyroid nodule. *Br J Surg*. 1972;59(7):545-8.
17. Prakash A, Moulik BK, Sharma LK, Kapur M, Poddar PK. Carcinoma of thyroid gland. A clinical study. *Ind J Surg*. 1974;43:409-16.
18. Godinho-Matos L, Kocjan G, Kurtz A. Contribution of fine needle aspiration cytology to diagnosis and management of thyroid disease. *J Clin Pathol*. 1992;45: 391-5.
19. Sheikh IA, Waleem SS, Haider IZ, Haroon A, Ashfaq M. Total thyroidectomy as primary elective procedure in multinodular 5 thyroid disease. *J Ayub Med Coll Abbottabad*. 2009;21(4):57-9.
20. Sushel C, Khanzada TW, Zulfikar I, Samad A. Histopathological pattern of diagnoses in patients undergoing thyroid operations. *Rawal Med J*. 2009;34:14-6.
21. Manzoor A, Khan F, Jamal S. Frequency of malignancy in multi-nodular goiter: A tertiary care hospital experience. *Journal of Islamabad Medical & Dental College (JIMDC)*. 2015;4(2):64-7.
22. Benzarti S, Miled I, Bassoumi T, Ben Mrad B, Akkari K, Bacha O, et al. Thyroid surgery (356 cases): the risks and complications. *Rev Laryngol OtolRhinol (Board)*. 2002;123(1):33-37.

23. Gandolfi PP, Frisina A, Raffa M, Renda F, Rocchetti O, Ruggeri C, et al. The frequency of thyroid carcinoma in multi-nodular goitre: A retrospective analysis. *Acta Bio Medica Ateneo Parmense*. 2004;75:114-7.

© 2020 Behan et al.; This is an Open Access article distributed under the terms of the Creative Commons Attribution License (<http://creativecommons.org/licenses/by/4.0>), which permits unrestricted use, distribution, and reproduction in any medium, provided the original work is properly cited.

Peer-review history:
The peer review history for this paper can be accessed here:
<http://www.sdiarticle4.com/review-history/53764>