

# Delayed Presentation and Surgical Intervention of Accidental Non-sex Related Penile Fracture with Urethral Injury: A Case Report

Friday Emeakpor Ogbetere <sup>a\*</sup> and Omigie Ann Erohubie <sup>b</sup>

<sup>a</sup> Department of Surgery, College of Medical Sciences, Edo State University, Uzairue, Edo State, Nigeria.

<sup>b</sup> Department of Radiology, College of Medical Sciences, Edo State University, Uzairue, Edo State, Nigeria.

## **Authors' contributions**

*This work was carried out in collaboration between both authors. Both authors read and approved the final manuscript.*

## **Article Information**

### **Open Peer Review History:**

This journal follows the Advanced Open Peer Review policy. Identity of the Reviewers, Editor(s) and additional Reviewers, peer review comments, different versions of the manuscript, comments of the editors, etc are available here: <https://www.sdiarticle5.com/review-history/98373>

**Case Study**

**Received: 03/02/2023**

**Accepted: 05/04/2023**

**Published: 11/04/2023**

## **ABSTRACT**

Penile fracture is a rare and unusual pathology resulting from a tear of the tunica albuginea of an erect penis. It is typically associated with sexual intercourse, masturbation, and a fall on or rolling over an erect penis. A cracking or popping sound followed by acute pain, rapid detumescence, and swelling of the penile shaft are frequent presenting symptoms. Prompt surgical intervention with repair of the tunica albuginea tear is the treatment of choice with satisfactory cosmetic and functional results.

We report the case of a 38-year-old man who presented to our urology outpatient clinic with a twenty-three-day history of penile trauma resulting from a forceful attempt to pull out his erect penis to urinate. Immediate penile exploration was performed following a diagnosis of penile fracture. He was found to have a tear of the tunica albuginea of the right corpora cavernosa with a urethral

\*Corresponding author: Email: [fridayemeakpor@gmail.com](mailto:fridayemeakpor@gmail.com);

injury which was repaired successfully. This case of atypical aetiology, delayed presentation, and surgical intervention of penile fracture highlights the importance of maintaining a high index of suspicion in diagnosing this rare condition, even in the absence of a typical mechanism of injury, in order to ensure that such injury is not missed.

**Keywords:** Penile fracture; penile trauma; albuginea tear; urethral injury; delayed presentation.

## 1. INTRODUCTION

Penile fracture is a rare blunt trauma to the erect penis during sexual intercourse or masturbation resulting in the sudden rupture of the tunica albuginea of one or both corpora cavernosa [1]. When the erect penis bends unusually, the sudden rise in intracavernosal pressure exceeds the tensile strength of the tunica albuginea, and a transverse tear of the tunica albuginea results [1].

Penile fractures are classically recognized as a urological emergency requiring urgent management [2]. The diagnosis is made through a thorough history and physical examination. Generally, patients often volunteer a history of an audible snap, immediate penile detumescence, and acute penile pain [3]. In indeterminate cases, investigations such as penile ultrasonography, magnetic resonance imaging (MRI), and cavernosography have been useful in establishing the diagnosis and localizing the site of the tear [3,4].

Prompt surgical exploration and repair of tunica albuginea tear is the current standard of care with a lower rate of complications compared to conservative management [3,5]. Delayed repair of penile fracture may occur due to delayed presentation after initial injury, misdiagnosis, or in patients who initially select conservative management [4,6].

We report a case of penile fracture with an atypical aetiology, presenting to our facility after twenty-three days. He had penile exploration and repair of both tunica albuginea tear and urethral rupture with good outcomes.

## 2. CASE REPORT

A 38-year-old married man presented to our urology clinic on referral with complaints of penile swelling, absent erection, and intermittent bleeding per urethra following accidental penile injury. He had sustained penile injury twenty-three days before presentation when he attempted to hurriedly manipulate his erect penis

out of his trousers to urinate. Immediately, he noticed a sudden sharp penile pain with rapid detumescence of the penis. He was able to complete the micturition process though with much difficulty. About 4 hours later, he noticed penile swelling and penile deviation to the left side and urethral bleeding necessitating his presentation to a primary care physician. There he was admitted and given antibiotics for 10 days. The antibiotics were repeated for seven days when the bleeding per urethra persisted after the first course. He was referred to our facility due to persistence of symptoms.

On physical examination, there was a right-sided ventrolateral mid penile shaft swelling with a left-sided deviation of the penis (Fig. 1). There was a palpable defect at the fracture site. Both testes were normal with no swelling in the scrotum and pubis.

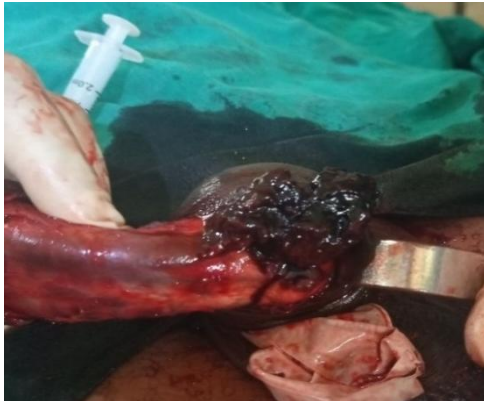

**Fig. 1. Physical examination in delayed presentation. Penile swelling with left-sided deviation following the penile injury**

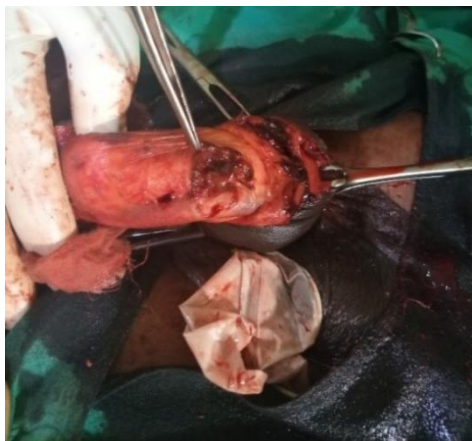Penile ultrasonography showed the presence of haematoma in the midshaft of the penis (3.5 x 2.8 cm) with a transverse rupture of the tunica albuginea of the right cavernosal corpora (10 mm) and oedema of the subcutaneous tissue. He had penile exploration after giving informed consent. Under spinal anesthesia, a subcoronal circumscising penile incision was made and the penis degloved. Massive hematoma which was limited by Buck fascia was seen (Fig. 2).

A transverse tear in the lateral aspect of the tunica albuginea of the right corporal cylinder was noted following a thorough evacuation of the haematoma (Fig. 3).

A size 18 Foleys catheter was passed into the bladder revealing a concomitant transverse urethral tear of about 0.5cm (Fig. 4). The tunica albuginea and the urethral tears were repaired with 3/0 vicryl sutures.



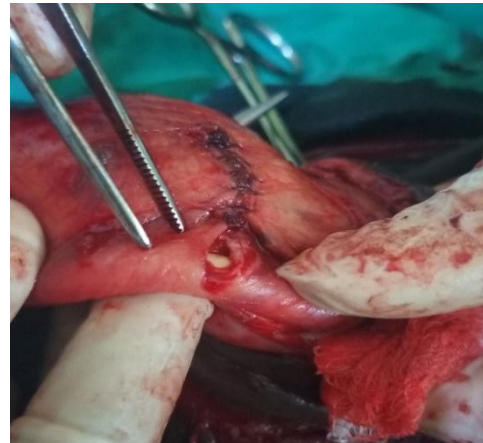
**Fig. 2. Haematoma at the site of penile injury**



**Fig. 3. Defect after the evacuation of haematoma**

For leakage control, artificial erection was provided by saline injected into the right corpus cavernosum. The patient had an uneventful postoperative recovery. Urethral catheter was removed on postoperative day seven and the patient was discharged on oral antibiotic treatment. He was advised to abstain from sexual intercourse for at least 4 weeks.

At six-week (Fig. 5) and 6-month follow-up, the patient had no residual deformity, and no erectile dysfunction. He was also voiding freely.



**Fig. 4. Urethral defect with an exposed urethral catheter**



**Fig. 5. Good aesthetic appearance six weeks after surgery**

### 3. DISCUSSION

Penile fracture is a rare urological emergency resulting from the tear of the tunica albuginea of an erect penis. In erection, the tunica albuginea covering the corporal bodies usually stretched out. This makes it easy to rupture when it is strained by any form of manipulation [1]. Although penile fracture is grossly underreported in sub-Saharan Africa due to the embarrassing nature of the pathology, its incidence has been on the increase [3].

Varied factors ranging from self-manipulation and vigorous sexual intercourse [3,4,7] to rolling over an erect penis while asleep and assault-related injuries have been reported to be responsible for aetiology of penile fracture [3]. In this index case, the penile fracture occurred as a result of unintentional, non-masturbatory, non-sex related trauma. The patient inadvertently exerted

excessive force while pulling out his erect penis to urinate. This unusual mechanism of penile fracture is extremely uncommon. The rarity of this mechanism of injury resulted in the misdiagnosis and delay in appropriate intervention or early referral by the first contact healthcare provider. A high index of suspicion, therefore, would facilitate prompt diagnosis and early treatment, maximizing the chance of a good long-term clinical outcome.

Generally, the diagnosis of penile fracture is isclinical. A typical history of a cracking or popping sound, acute penile pain, and immediate detumescence at the time of injury are often volunteered by the patients. Also, patients with penile fracture commonly develop progressive penile swelling and penile deviation often called 'eggplant deformity.' Symptoms of bleeding per urethra, haematuria, and acute retention of urine in patients with a penile fracture are suggestive of urethral injuries. The physical examination may show penile swelling, penile curvature, and a defect at the point of the tunica albuginea tear. The absence of typical symptoms and signs, as in this index case, can pose a real challenge. Therefore, a thorough history and physical examination are key in the diagnosis of penile fracture.

An ultrasound scan may aid the history and examination findings, especially in patients with a suspected penile fracture with atypical history as in this case report. This may show haematoma and the defect in the tunica albuginea [8]. Other imaging investigations like MRI and cavernosography may be useful in indeterminate cases. Retrograde urethrography and cystoscopy may be done in patients with suspected urethral injuries [3]. However, these investigations are not readily available and may add to the delay in surgical intervention.

Immediate surgical exploration is the recommended standard treatment of penile fracture [3,4]. However, delayed repair has also been associated with good outcomes [6]. A subcoronal circumscribing incision has been advocated as it allows complete exposure of all corporal bodies along the entire shaft [9]. Tunica albuginea tears should be repaired with absorbable sutures with buried knots. Urethral injuries, if present as in this reported case, should be repaired at the time. Surgical intervention, both immediate and delayed, is reported to be safe with the restoration of erectile function compared to controls and

high patient and partner satisfaction levels [3,4,7].

#### 4. CONCLUSION

Penile fracture is a rare urological emergency. Though classical, the aetiology and modes of presentation of penile fracture could be atypical. The first contact physician must be aware of the less common mechanism of injury, the atypical modes of presentation, and exercise a high index of suspicion to avoid delay in diagnosis and inappropriate urological management which can increase complications of penile fracture.

#### CONSENT

Consent was obtained from the parents of patient for the publication of his information in the medical journal.

#### ETHICAL APPROVAL

As per international standard or university standard written ethical approval has been collected and preserved by the author(s).

#### COMPETING INTERESTS

Authors have declared that no competing interests exist.

#### REFERENCES

1. Bitsch M, Kromann-Andersen B, Schou J, Sjøntoft E. The elasticity and the tensile strength of tunica albuginea of the corpora cavernosa. *J Urol.* 1990;143:642-5.
2. Bella AJ, Shamloul R. Addressing the barriers to optimal management of penile fracture. *Can Urol Assoc J.* 2013;7:258-9.
3. Eke, N. Fracture of the penis. *Br J Surg.* 2002;89:555-65.
4. Zargooshi J. Penile fracture in Kermanshah, Iran: Report of 172 cases. *J Urol.* 2000;164:364-6.
5. Wong NC, Dason S, Bansal RK, Davies TO, Braga LH. Can it wait? A systematic review of immediate vs. delayed surgical repair of penile fractures. *Can Urol Assoc J.* 2017;11:53-60.
6. Ogbetere FE. Double penile fracture without urethral injury presenting after 7 days. *Ann Afr Med.* 2022;21:102-5.

7. Sawh SL, O'Leary MP, Ferreira MD, Berry AM, Maharaj D. Fractured penis: A review. Int J Impot Res. 2008;20:366–9
8. <sup>1</sup>.Ash A, Miller J, Preston D. Point of care ultrasound used to exclude penile fracture. Crit Ultrasound J. 2012;4:17.
9. Kamdar C, Mooppan UM, Kim H, Gulmi FA. Penile fracture: Preoperative evaluation and surgical technique for optimal patient outcome. BJU Int. 2008; 102:1640–4.

---

© 2023 Ogbetere and Erohubie; This is an Open Access article distributed under the terms of the Creative Commons Attribution License (<http://creativecommons.org/licenses/by/4.0>), which permits unrestricted use, distribution, and reproduction in any medium, provided the original work is properly cited.

*Peer-review history:*  
*The peer review history for this paper can be accessed here:*  
<https://www.sdiarticle5.com/review-history/98373>