



## **Overview on Causes, Diagnosis and Management of Knee Injuries in Children and Adolescents: Review Article**

**Nazim Faisal Hamed<sup>a\*#</sup>, Mohammed Hussen Sheikha<sup>b≡</sup>,  
Ahmed Sughayyir Albalawi<sup>c</sup>, Abdulrahman Abdullah Aloufi<sup>d</sup>,  
Abdullah Khalaf A. Alshammari<sup>e</sup>, Sawsan Musri Althubyani<sup>f</sup>,  
Nouf Dhaifallah Ali Almatrafi<sup>f</sup>, Emtenan Adel Hussain Saraj<sup>g⊖</sup>  
and Manal Mohammed E. Alhawiti<sup>h</sup>**

<sup>a</sup> *Maternal and Child Health Care Center, Tabuk, Saudi Arabia.*

<sup>b</sup> *Department of Pediatrics, Faculty of Medicine, Tabuk University, Saudi Arabia.*

<sup>c</sup> *Pediatric Emergency Fellow, Security Forces Hospital, Riyadh, Saudi Arabia.*

<sup>d</sup> *Pediatric Registrar, Qassim Armed Forces Hospital, Saudi Arabia*

<sup>e</sup> *Pediatrics Resident, Maternal and Child Health Care Center, Tabuk, Saudi Arabia.*

<sup>f</sup> *Faculty of Medicine, Northern Borders University, Arar, Kingdom of Saudi Arabia.*

<sup>g</sup> *North Medical Tower, ArAr City, KSA.*

<sup>h</sup> *General practitioner, Maternity & Children Hospital, Tabuk, Saudi Arabia.*

### **Authors' contributions**

*This work was carried out in collaboration among all authors. All authors read and approved the final manuscript.*

### **Article Information**

DOI: 10.9734/JPRI/2021/v33i59A34245

### **Open Peer Review History:**

This journal follows the Advanced Open Peer Review policy. Identity of the Reviewers, Editor(s) and additional Reviewers, peer review comments, different versions of the manuscript, comments of the editors, etc are available here:

<https://www.sdiarticle5.com/review-history/78767>

**Review Article**

**Received 10 October 2021**

**Accepted 14 December 2021**

**Published 16 December 2021**

## **ABSTRACT**

This review aimed to summarize the updates in the causes, diagnosis and management of knee injuries in children and adolescents. Knee injuries are common and are often the result of multiple forces: varus, valgus, hyperextension, hyperflexion, internal rotation, external rotation, anterior or posterior translation, and axial loading. Certain combinations of force are known to cause specific patterns of injury. A knee injury can affect any ligaments, tendons, or fluid-filled sacs (bursae) that

<sup>#</sup> *Consultant of Pediatrics;*

<sup>≡</sup> *Head;*

<sup>⊖</sup> *Nursing specialist;*

<sup>\*</sup>*Corresponding author: E-mail: nazim\_prof@yahoo.com*

surround the knee joint, as well as the bones, cartilage, and ligaments that make up the joint itself. ACL injuries are one of the most common types of knee injuries, including a torn meniscus that is common in sports that require jumping jacks, patellar fractures, and knee bruises. Magnetic resonance imaging (MRI) is often used to more fully evaluate knee injuries. Radiologists can accurately identify individual lesions and combinations of lesions. Surgical and non-surgical treatments are performed depending on the case.

*Keywords: review, updates, causes, diagnosis, management, knee injuries, children, adolescents.*

## 1. INTRODUCTION

Trauma and injuries in childhood and adolescence are common, and the knee is one of the most common injury sites [1].

Knee injuries in child and adolescent athletes can be caused by an acute traumatic injury, such as a sudden fall or chronic repetitive strain injury. Occasionally, a knee injury can be the result of a combination of both factors - an athlete may have a chronic problem that suddenly worsens due to an acute traumatic event. These injuries can cause various symptoms such as pain, shakiness, swelling and stiffness [2].

When an active young man complains of knee pain, the treating pediatrician must be comfortable making a functioning differential diagnosis and should be able to manage many of these injuries or recognize when appropriate referral is needed [3].

Knee injury can affect any of the ligaments, tendons or fluid-filled sacs (bursae) that surround knee joint as well as the bones, cartilage and ligaments that form the joint itself. Some of the most common knee injuries include: Ligament Injuries (ACL, PCL, CL) anterior cruciate ligament (ACL) injury is the most common one,

torn meniscus, patellar fracture, knee bursitis and other inflammatory conditions [4].

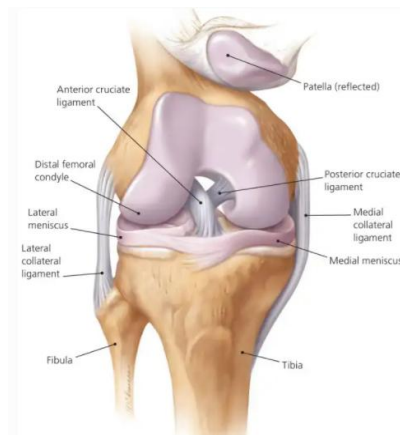
However, Kraus et al. [5] stated that, knee injuries in children and adolescents are rare, and extra-articular soft tissue injuries are the most common type of knee trauma. The number of knee injuries and their severity increase with age, predominantly the male part. Sports facilities and traffic accidents are major scenarios for knee injuries. The mechanisms and patterns evaluated in this study can serve as the basis for efforts to prevent knee injuries in children and adolescents, and for necessary precautionary measures.

This review looks at the updates in the causes, diagnosis and management of knee injuries in children and adolescents.

## 2. THE MOST COMMON KNEE INJURIES

### 2.1 Anterior Cruciate Ligament Injuries

The anterior cruciate ligament (ACL) is one of 2 cruciate ligaments that aids in stabilizing the knee joint [6]. It is a strong band made of connective tissue and collagenous fibers that originate from the anteromedial aspect of the intercondylar region of the tibial plateau and extends posteromedially to attach to the lateral femoral condyle. (Fig. 1).



**Fig. 1. The tibial plateau and extends posteromedially to attach to the lateral femoral condyle**

The anteromedial bundle and posterolateral bundle form the 2 components of the ACL. The ACL and the posterior cruciate ligament (PCL) together form a cross (or an "x") within the knee and prevent excessive forward or backward motion of the tibia relative to the femur during flexion and extension [7]. The ACL additionally provides rotational stability to the knee with varus or valgus stress. The annual reported incidence in the United States alone is approximately 1 in 3500 people. Most ACL tears occur in athletes by noncontact mechanisms versus contact mechanisms, such as rotational forces versus a direct hit to the knee [8]. The most at-risk athletes for noncontact injury include skiers, soccer players, and basketball players, while the most at-risk athletes for contact injury are football players [9]. Typically, injury occurs during activity/sports play that includes sudden changes in the direction of movement, rapid stopping, jumping and landing abnormally, a direct blow to the lateral aspect of the knee, or slowing down while running. Most patients complain of hearing and feeling a sudden "pop" and feel that their knee "gives out" from under them at the time of injury. Other symptoms include tenderness along the joint line, pain, and swelling, decreased or loss of range of motion, and difficulty ambulating [10]. The physical exam should include timing of the injury, mechanism of injury, ambulatory status, joint stability, mobility, strength, palpation, and evaluation of possible associated injuries. Imaging with magnetic resonance (MRI) is often utilized to confirm the diagnosis [11]. MRI is the primary modality to diagnose ACL pathology with a sensitivity of 86% and specificity of 95%. Diagnosis may also be made with knee arthroscopy to differentiate complete from partial tears and chronic tears. Arthrography is considered the gold standard as it is 92% to 100% sensitive and 95% to 100% specific; however, it is rarely used as the initial step in diagnosis as it is invasive and requires anesthesia. ACL injuries, depending upon their severity, can be managed non-operatively or operatively [12]. The patient with an anterior cruciate ligament injury should be referred to the orthopedic physician to discuss treatment options and a physical therapist (PT) for rehabilitation. No operative treatment is typically reserved for those with low functional demands, type and severity of ACL tear, time of injury, and subsequent assessment. The decision to undergo operative treatment is based upon many factors such as the patient's baseline level of physical activity, functional demands, age,

occupation, and other associated injuries, if present [13].

## 2.2 Knee Meniscal Tears

The lateral and medial menisci are crescent-shaped fibrocartilaginous structures that collectively cover approximately 70% of the articular surface of the tibial plateau and primarily function in load transmission and shock absorption through the tibiofemoral joint. The patient's clinical presentation with a meniscal tear is variable depending on the mechanism of injury and degree of concomitant tibiofemoral insults. The sensation of a "pop," with immediate effusion of the knee during high-impact activity or trauma, is associated with an ACL tear with a possible associated medial meniscal tear [14]. In contrast, effusion that develops more gradually over the course of 24 hours is more indicative of an isolated meniscal tear. Symptoms can also be insidious in nature, in which low-grade effusion and stiffness develop over the course of several days despite the absence of an inciting event. Pain is typically reported over the anteromedial or anterolateral joint line. Depending on the type and extent of the meniscal lesion, there may also be symptoms of locking, clicking, catching, intermittent inability to fully extend the knee, or feeling of the knee giving way [15].

Physical examination should include inspection of the knee for edema, palpation of the joint line, standing and supine range of motion (ROM), muscle strength testing, and special testing. Anteromedial and anterolateral joint line tenderness performed with the patient's knee at the edge of the table at 90 degrees of flexion is 83% sensitive and 83% specific for a meniscal tear. There may be pain and deficits in either flexion or extension ROM depending on the type of tear and extent of effusion. Deficits in open kinetic chain knee flexion/extension strength testing are unlikely [16]. Still, antalgic gait or increased pain with single or double-leg squatting is possible due to increased compressive forces over the menisci. There are several provocative special tests for the detection of meniscal tears [17]. The Thessaly test, in which the patient stands on one leg, squats down to 20 degrees of flexion, and internally/externally rotates the knee through active adduction/abduction of the hip, is 75% sensitive and 87% specific. McMurray's test has a sensitivity of 61% and specificity of 84%. It involves passively extending the supine patient's knee from a fully flexed position to 90 degrees

flexion while maintaining full external or internal rotation [18]. Apley's compression test, in which the prone patient's knee is passively flexed to 90 degrees and then externally/internally rotated with axial compressive force through the knee, is < 20% sensitive and up to 80% to 90% specific. When a meniscal tear is suspected, imaging should begin with radiographs that include AP, lateral, oblique, sunrise, and weight bearing views to assess for concomitant bony pathologies, loose bodies, and osteoarthritis. Using arthroscopy as the gold standard, MRI is the best mode of imaging to diagnose and characterize meniscal tears. MR imaging has been found to be 93% sensitive and 88% specific for medial meniscal tears, and 79% sensitive and 96% specific for lateral meniscal tears [19]. Initial treatment of the acutely painful, edematous knee in which meniscal tear is suspected should consist of the RICE principles for acute soft tissue injury (rest, ice, compression, and elevation) [20]. Oral analgesics and NSAIDs may be prescribed to reduce pain and swelling. Bracing or knee sleeves may be used for protection and compression, and early pain-free knee and ankle ROM exercise may help to limit the loss of motion and aid in edema control. For simple tears confined to the outer 1/3 of the meniscus and degenerative tears, it is reasonable to perform a 4-6 week course of relative rest and physical therapy to determine if spontaneous healing and return to the desired level of function will occur [21]. Despite conservative management, patients with

persistent pain, swelling, and mechanical symptoms should be assessed for potential surgical intervention. For tears requiring arthroscopic surgery, meniscal repair is preferred over meniscectomy if possible since the risk of accelerated osteoarthritis increases with the removal of meniscal tissue due to decreased cushioning and increased force transmission across articular cartilage surfaces [22]. Factors that increase the likelihood of successful meniscal repair include tears that occur in the red zone of the meniscus, tears that are shorter than 2cm, vertical longitudinal tears, and acute tears. Rehabilitation following meniscal repair typically includes restrictions in knee flexion ROM and the weight-bearing status during the first 6 weeks postoperatively, depending on the location of the tear and type of repair. Meniscal allograft transplantation is considered a salvage procedure for symptomatic patients less than 50y/o with a meniscus-deficient compartment and otherwise stable knee [23].

### 2.3 Patellar Fracture

The patella is the largest sesamoid bone in the human body. The posterior aspect of the patella contains a thick cartilage layer, which is the thickest cartilage in the body. A vertical ridge separates the medial and lateral facets of the articular surface and articulates with the femoral trochlea [24]. (Fig. 2).

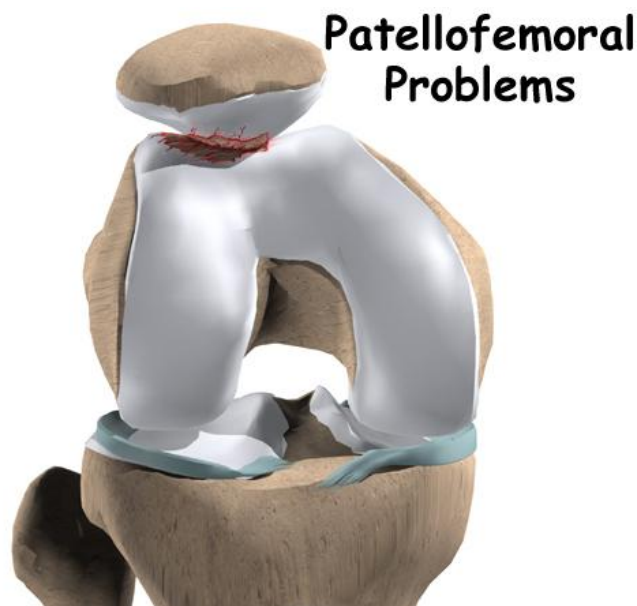

Fig. 2.

The patella protects the anterior aspect of the knee joint. Fractures of the patella may be due to direct or indirect forces, and the mechanism of injury often determines the fracture pattern. The patella most commonly fails indirectly under tension. Eccentric forces from the extensor mechanism may overpower the mechanical properties of the bone. Due to the patella's subcutaneous position, a direct injury may result from a blow to the anterior knee, such as from a fall or impact from the dashboard in a motor vehicle accident. Fractures of the patella account for approximately 1% of all fractures. They occur more commonly in males. Open injuries account for 6% to 9% of patellar fractures and are commonly associated with other injuries given the high energy mechanism [25]. A thorough history and physical examination are necessary to identify the injury mechanism and other potential injuries. Palpation of closed injuries may reveal crepitus, fracture gap, and swelling indicative of hemarthrosis. A straight-leg test must be performed to assess the extensor mechanism, although this may be limited secondary to pain.

Periprosthetic fractures of the patella may not present the same as native patella fractures. Trauma is a significant cause of periprosthetic patellar fractures; however, some patients may not recall a single episode that is responsible for a fracture. At the time of diagnosis, forty-four percent of patients with a traumatic periprosthetic patellar fractures complained of minimal or no symptoms [26]. Similar to the native patellar fractures, traumatic injuries present with diffuse anterior knee pain, tenderness to palpation, effusion, weakness, instability, and difficulty with stairs.

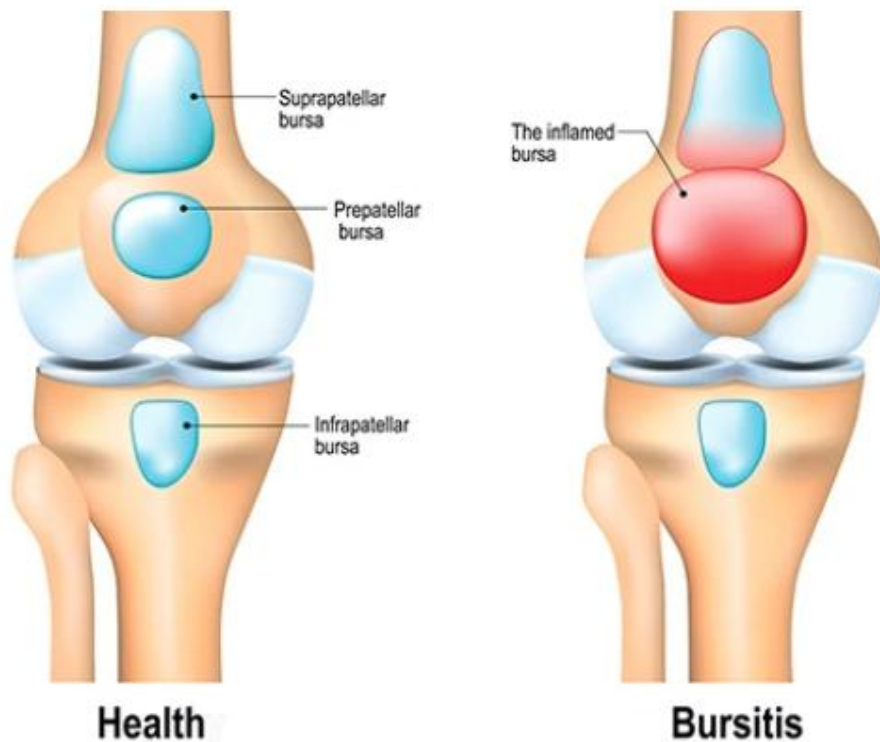
Radiographic evaluation with anteroposterior (AP) and lateral knee radiographs should be obtained. Lateral views are useful to assess for the displacement of the patellar fragments [27]. Advanced imaging of patellar fractures is rarely warranted. Imaging of bipartite patella most commonly demonstrates a fragment at the superolateral pole. They can be differentiated from acute fractures by the appearance of smooth edges. Imaging of the contralateral knee may reveal a bilateral bipartite patella in up to 50% of cases [28].

Patients with suspected periprosthetic patellar fractures should be evaluated with formal anteroposterior, lateral, and skyline radiographs. In rare situations, a Technetium-99m bone scan

may be of use to diagnose an occult fracture or to differentiate from an acute or chronic fracture [29]. Careful interpretation of a bone scan is required as this type of scan may be positive for 48 months following the initial injury.

Restoration of the extensor mechanism is the primary treatment goal for patellar fractures. No operative management is indicated for minimally displaced fractures (less than 2 to 3 mm of step-off and less than 1 to 4 mm fracture gap) with the extensor mechanism in continuity [30]. Patients with displaced patellar fractures who are not medically or psychologically fit for surgery may also undergo a trial of no operative treatment. A long-leg splint, knee immobilizer, or hinged knee brace locked in extension can be used to stabilize the fracture while allowing early weight-bearing. Physical therapy is recommended after the pain subsides to work on the active and active-assisted range of motion. Repeat radiographs should be obtained a week after initiation of motion exercises to evaluate for fracture displacement. Approximately six weeks after the initial injury, the patient can be started on resistance exercises [31].

Open reduction and internal fixation are indicated for open fractures, substantially displaced fractures, and fractures with a loss of extensor function. Urgent irrigation, debridement, and antibiotic treatment are indicated for open fractures [32]. Evolutions of the surgical treatment led to the modified anterior tension band (MATB) technique, which combines an 18-gauge stainless-steel wire in a figure-of-eight configuration wrapped around two vertical Kirschner wires (K-wires). According to the AO, the MATB technique should be combined with an additional cerclage around the patella to supplement the fixation for comminuted patellar fractures [33]. Wire migration and soft tissue irritation have prompted research into alternative materials and minimally invasive approaches. Despite the variety of techniques and instrumentations described in the literature, high union rates and clinical outcomes based on the Bostman grading scale have been reported after surgical fixation. Other methods of fixation include tension band plating along the anterior surface, as well as circumferential cerclage wiring or plating around the perimeter of the patella. These methods of fixation are typically reserved for highly comminuted fractures in which tension band principles cannot be used [34].



**Fig. 3. On MRI imaging, bursitis appears as an oblong fluid collection in its expected anatomical location**

## 2.4 Knee Bursitis

A bursa is a fluid-filled structure that is present between the skin and tendon or tendon and bone. The main function of a bursa is to reduce friction between adjacent moving structures. Typically, bursae are located around large joints such as the shoulder, knee, hip, and elbow. Inflammation of this fluid-filled structure is called bursitis [35]. Trauma, infection, overuse, and hemorrhage are some of the common causes for inflammation. Other causes include systemic illness like collagen vascular disease and inflammatory arthropathy; in some instances the cause is unknown [36]. Some cases of bursitis are associated with certain occupations and are named accordingly; for instance, prepatellar bursitis is also known as housemaid's knee and superficial infrapatellar bursitis is synonymous with clergyman's knee [37].

Bursae around the knee can be grouped as those that occur around the patella and those that occur elsewhere [38]. Bursae around the patella include the prepatellar bursa, the superficial and deep infrapatellar bursae, and the suprapatellar bursa. Bursae that are not anatomically close to the patella include the pes

anserine bursa, the iliotibial bursa, the tibial and fibular collateral ligament bursae and the gastrocnemius-semimembranosus bursa. On MRI imaging, bursitis appears as an oblong fluid collection in its expected anatomical location [39] (Fig. 3).

## 3. CONCLUSION

Knee injuries are common, often resulting from multiple forces: Varus, valgus, hyperextension, hyperflexion, internal rotation, external rotation, anterior or posterior translation, and axial load. Certain combinations of forces are known to cause specific injury patterns. Knee injury can affect any of the ligaments, tendons or fluid-filled sacs (bursae) that surround knee joint as well as the bones, cartilage and ligaments that form the joint itself. ACL injuries are one of the most common types of knee injuries, also meniscus tears which are common in sports that require jumping, patellar fracture, and knee bursitis. Magnetic resonance (MR) imaging is widely used to assess knee injuries more completely. Radiologists are accurate at detecting individual injuries and combinations of injuries. Operative and non-operative treatment are done according to the case.

## CONSENT

It is not applicable.

## ETHICAL APPROVAL

It is not applicable.

## COMPETING INTERESTS

Authors have declared that no competing interests exist.

## REFERENCES

1. Adirim TA, Cheng TL, Overview of injuries in the young athlete. 2003;33(1):75–81, PMID: 12477379, DOI: 10.2165/00007256-200333010-00006
2. Ingram JG, Yard EE, Fields SK, Comstock RD, Epidemiology of knee injuries among boys and girls in US high school athletics. *Am J Sports Med* (2008) 36(6):1116–1122
3. Gupte C, St Mart JP. The acute swollen knee: diagnosis and management. *J R Soc Med.* 2013 Jul;106(7):259-68. doi: 10.1177/0141076813482831.PMID:23821708;PMCID: PMC3704066.
4. Gupta R, Malhotra A, Sood M, Masih GD. Is anterior cruciate ligament graft rupture (after successful anterior cruciate ligament reconstruction and return to sports) actually a graft failure or a re-injury? *J Orthop Surg (Hong Kong).* 2019 Jan-Apr;27(1):2309499019829625. [PubMed]
5. Hoogeslag RAG, Brouwer RW, Boer BC, de Vries AJ, Huis In 't Veld R. Acute Anterior Cruciate Ligament Rupture: Repair or Reconstruction? Two-Year Results of a Randomized Controlled Clinical Trial. *Am J Sports Med.* 2019 Mar;47(3):567-577. [PubMed]
6. Barfod KW, Rasmussen R, Blaabjerg B, Hölmich P, Lind M. [Return to play after anterior cruciate ligament reconstruction]. *Ugeskr Laeger.* 2019 Feb 18;181(8) [PubMed]
7. Kraus T, Švehlík M, Singer G, Schalamon J, Zwick E, Linhart W. The epidemiology of knee injuries in children and adolescents. *Arch Orthop Trauma Surg.* 2012 Jun;132(6):773-9.
8. Davey A, Endres NK, Johnson RJ, Shealy JE. Alpine Skiing Injuries. *Sports Health.* 2019 Jan/Feb;11(1):18-26. [PMC free article] [PubMed]
9. Eberl R. [Anterior cruciate ligament rupture in children with open growth plate : Diagnostics and treatment]. *Unfallchirurg.* 2019 Jan;122(1):17-21. [PubMed]
10. Palazzolo A, Rosso F, Bonasia DE, Saccia F, Rossi R., Knee Committee SIGASCOT. Uncommon Complications after Anterior Cruciate Ligament Reconstruction. *Joints.* 2018 Sep;6(3):188-203. [PMC free article] [PubMed]
11. Benjaminse A, Webster KE, Kimp A, Meijer M, Gokeler A. Revised Approach to the Role of Fatigue in Anterior Cruciate Ligament Injury Prevention: A Systematic Review with Meta-Analyses. *Sports Med.* 2019 Apr;49(4):565-586. [PMC free article] [PubMed]
12. Losciale JM, Zdeb RM, Ledbetter L, Reiman MP, Sell TC. The Association Between Passing Return-to-Sport Criteria and Second Anterior Cruciate Ligament Injury Risk: A Systematic Review With Meta-analysis. *J Orthop Sports Phys Ther.* 2019 Feb;49(2):43-54. [PubMed]
13. Roth TS, Osbahr DC. Knee Injuries in Elite Level Soccer Players. *Am J Orthop (Belle Mead NJ).* 2018 Oct;47(10) [PubMed]
14. Thoma LM, Grindem H, Logerstedt D, Axe M, Engebretsen L, Risberg MA, Snyder-Mackler L. Coper Classification Early After Anterior Cruciate Ligament Rupture Changes With Progressive Neuromuscular and Strength Training and Is Associated With 2-Year Success: The Delaware-Oslo ACL Cohort Study. *Am J Sports Med.* 2019 Mar;47(4):807-814. [PMC free article] [PubMed]
15. Dejour D, Pungitore M, Valluy J, Nover L, Saffarini M, Demey G. Tibial slope and medial meniscectomy significantly influence short-term knee laxity following ACL reconstruction. *Knee Surg Sports Traumatol Arthrosc.* 2019 Nov;27(11):3481-3489. [PubMed]
16. van de Graaf VA, Willigenburg NW, Poolman RW. Arthroscopic Partial Meniscectomy vs Physical Therapy for Nonobstructive Meniscal Tears-Reply. *JAMA.* 2019 Feb 26;321(8):806. [PubMed]
17. Liebs TR. Arthroscopic Partial Meniscectomy vs Physical Therapy for Nonobstructive Meniscal Tears. *JAMA.* 2019 Feb 26;321(8):805-806. [PubMed]
18. Donohue MA, Zhou L, Haley CA. Meniscus Injuries in the Military Athlete. *J Knee Surg.* 2019 Feb;32(2):123-126. [PubMed]

19. Fuchs A, Kloos F, Bode G, Izadpanah K, Südkamp NP, Feucht MJ. Isolated revision meniscal repair - failure rates, clinical outcome, and patient satisfaction. *BMC Musculoskelet Disord.* 2018 Dec 21;19(1):446. [PMC free article] [PubMed]
20. Wilson PL, Wyatt CW, Romero J, Sabatino MJ, Ellis HB. Incidence, Presentation, and Treatment of Pediatric and Adolescent Meniscal Root Injuries. *Orthop J Sports Med.* 2018 Nov;6(11):2325967118803888. [PMC free article] [PubMed]
21. Kurzweil PR, Cannon WD, DeHaven KE. Meniscus Repair and Replacement. *Sports Med Arthrosc Rev.* 2018 Dec;26(4):160-164. [PubMed]
22. Karia M, Ghaly Y, Al-Hadithy N, Mordecai S, Gupte C. Current concepts in the techniques, indications and outcomes of meniscal repairs. *Eur J Orthop Surg Traumatol.* 2019 Apr;29(3):509-520. [PMC free article] [PubMed]
23. Hollier J, Leonardi C, Igbokwe L, Dasa V. Knee Range of Motion as a Discriminatory Tool Indicating Potential Meniscal Tears. *Ochsner J.* 2018 Summer;18(2):126-130. [PMC free article] [PubMed]
24. Chirichella PS, Jow S, Iacono S, Wey HE, Malanga GA. Treatment of Knee Meniscus Pathology: Rehabilitation, Surgery, and Orthobiologics. *PM R.* 2019 Mar;11(3):292-308. [PubMed]
25. Melvin JS, Mehta S. Patellar fractures in adults. *J Am Acad Orthop Surg.* 2011 Apr;19(4):198-207. [PubMed]
26. Kurtz S, Ong K, Lau E, Mowat F, Halpern M. Projections of primary and revision hip and knee arthroplasty in the United States from 2005 to 2030. *J Bone Joint Surg Am.* 2007 Apr;89(4):780-5. [PubMed]
27. Anand S, Hahnel JC, Giannoudis PV. Open patellar fractures: high energy injuries with a poor outcome? *Injury.* 2008 Apr;39(4):480-4. [PubMed]
28. Atesok K, Doral MN, Lowe J, Finsterbush A. Symptomatic bipartite patella: treatment alternatives. *J Am Acad Orthop Surg.* 2008 Aug;16(8):455-61. [PubMed]
29. Ortiguera CJ, Berry DJ. Patellar fracture after total knee arthroplasty. *J Bone Joint Surg Am.* 2002 Apr;84(4):532-40. [PubMed]
30. Sheth NP, Pedowitz DI, Lonner JH. Periprosthetic patellar fractures. *J Bone Joint Surg Am.* 2007 Oct;89(10):2285-96. [PubMed]
31. Tharani R, Nakasone C, Vince KG. Periprosthetic fractures after total knee arthroplasty. *J Arthroplasty.* 2005 Jun;20(4 Suppl 2):27-32. [PubMed]
32. Meinberg EG, Agel J, Roberts CS, Karam MD, Kellam JF. Fracture and Dislocation Classification Compendium-2018. *J Orthop Trauma.* 2018 Jan;32 Suppl 1:S1-S170. [PubMed]
33. Nord RM, Quach T, Walsh M, Pereira D, Tejwani NC. Detection of traumatic arthrotomy of the knee using the saline solution load test. *J Bone Joint Surg Am.* 2009 Jan;91(1):66-70. [PubMed]
34. Choi HR, Min KD, Choi SW, Lee BI. Migration to the popliteal fossa of broken wires from a fixed patellar fracture. *Knee.* 2008 Dec;15(6):491-3. [PubMed]
35. Koh WL, Kwek JW, Quek ST, Peh WC. Clinics in diagnostic imaging (77). Pes anserine bursitis. *Singapore Med J.* 2002;43:485-91. [PubMed] [Google Scholar]
36. Hirji Z, Hanjun JS, Choudur HN. Imaging of Bursae. *J Clin Imaging Sci.* 2011;1:22. [PMC free article] [PubMed] [Google Scholar]
37. McCarthy CL, McNally EG. The MRI appearance of cystic lesions around the knee. *Skeletal Radiol.* 2004;33:187-209. [PubMed] [Google Scholar]
38. Dorsey ML, Liu PT, Leslie KO, Beauchamp CP. Painful suprapatellar swelling: Diagnosis and discussion. (951-2). *Skeletal Radiol.* 2008;37:937-8. [PubMed] [Google Scholar]
39. Rennie WJ, Saifuddin A. Pes anserine bursitis: Incidence in symptomatic knees and clinical presentation. *Skeletal Radiol.* 2005;34:395-8. [PubMed] [Google Scholar]

© 2021 Hamed et al.; This is an Open Access article distributed under the terms of the Creative Commons Attribution License (<http://creativecommons.org/licenses/by/4.0>), which permits unrestricted use, distribution, and reproduction in any medium, provided the original work is properly cited.

Peer-review history:  
 The peer review history for this paper can be accessed here:  
<https://www.sdiarticle5.com/review-history/78767>